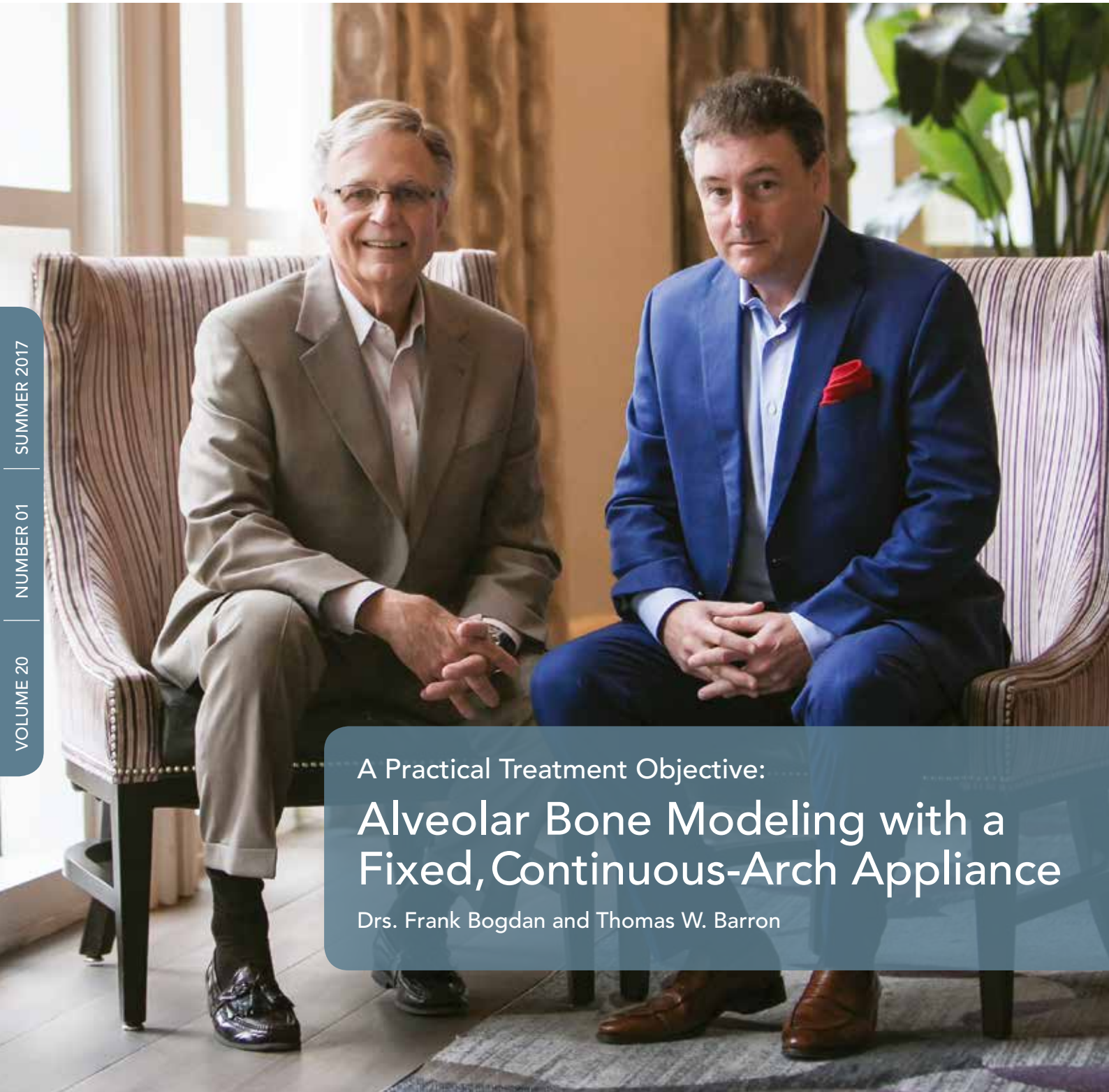



clinical impressions®

clinical & practice management orthodontic resource

VOLUME 20
NUMBER 01
SUMMER 2017



A Practical Treatment Objective:

Alveolar Bone Modeling with a Fixed, Continuous-Arch Appliance

Drs. Frank Bogdan and Thomas W. Barron

also in this issue

○ Case Study: Insignia™ Resolves Adult Open Bite with Straight-Wire™ Finishing
Dr. David González Zamora

○ Ortho CIS™ Article Revisited: "Practice Efficiency & Profitability"
Dr. Michael W. Scott

OPTIMAL AESTHETICS. PROVEN PERFORMANCE.

The Inspire ICE monocrystalline bracket features crystal-clear sapphire finishing for optimal aesthetics and unparalleled strength¹ that provides clinical performance during treatment while also offering safe, easier, single piece removal.²

To learn more, visit ormco.com, call **800-854-1741**, or speak with your Ormco representative.



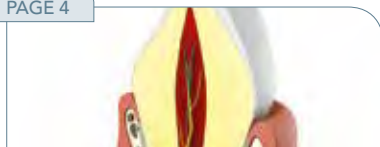inspire
ice™

1. Fracture Strength of Ceramic Bracket Tie Wings Subjected to Tension Gerald Johnson, DDS; Mary P. Walker, DDS, PhD; Katherine Kula, DDS, MSc Angle Orthodontist, Vol 75, No 1, 2005
2. Angle Orthodontist, Vol 85, No 4: 651-656, 2015

TABLE OF CONTENTS

clinical impressions® | vol. 20 | no. 01 | summer 2017

PAGE 4



A Practical Treatment Objective: Alveolar Bone Modeling with a Fixed, Continuous-Arch Appliance

Drs. Thomas W. Barron and Frank Bogdan
Maryland and New Jersey, USA

PAGE 23



Case Review: Insignia™ Resolves Adult Open Bite with Straight-Wire™ Finishing

Dr. David González Zamora
Madrid, Spain

PAGE 28



Ortho CIS™ Article Revisited: "Practice Efficiency & Profitability"

Dr. Michael W. Scott
Texas, USA

Subscribe to CI online

This edition and future issues of *Clinical Impressions* are available online at ormco.com/ci. To be notified of future issues, register today at ormco.com/ci.

Article Submissions

If you're interested in having an article considered for publication in *Clinical Impressions*, e-mail us at ci@ormco.com.



From the President

Dear Colleagues,

Welcome to this issue of *Clinical Impressions*, celebrating the 25th anniversary of its inaugural edition. Over the years, this publication has featured clinical and practice building insights from hundreds of your esteemed colleagues from around the world. It is an important part of Ormco's history, present and future and I thank all of our contributors and readers for their involvement.

In this issue, Drs. Barron and Bogdan offer studious research and clinical documentation of alveolar bone modeling, a profound benefit of light-force, low-friction mechanics that support the fundamental principles of Dr. Damon's teachings over the past 20 years.

Dr. Scott revisits his Ortho CIS™ twin appliance article that he wrote for *Clinical Impressions* 18 years ago, praising the system's clinical and practice management benefits which remains true to this day. He also shares how his skill development and treatment protocols allow him to use the Ortho CIS system to even greater advantage today.

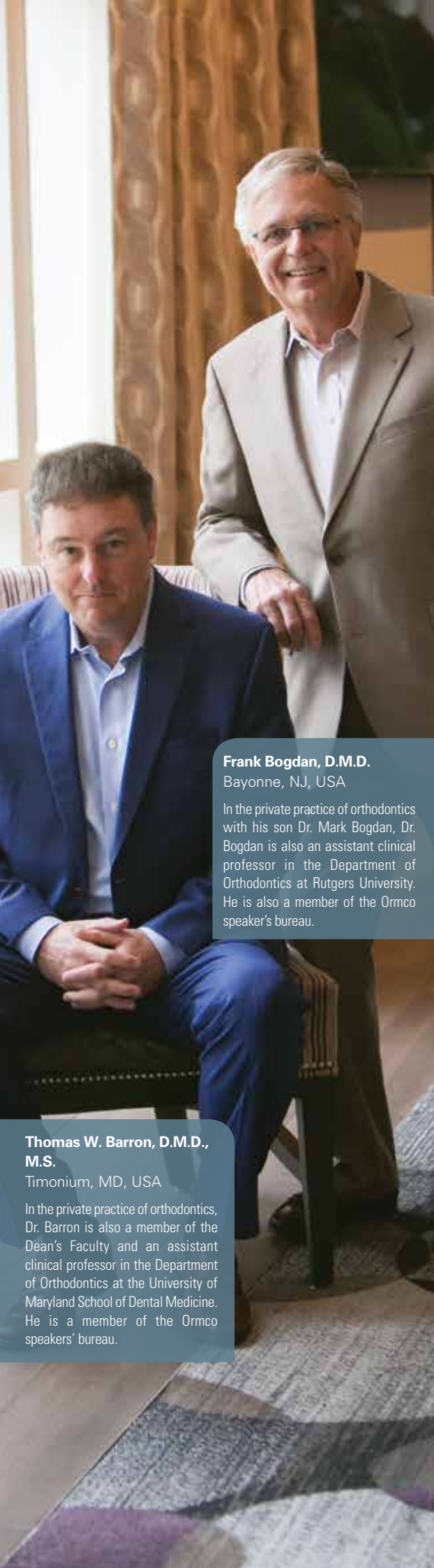Dr. Zamora's case presentation is a preview of his and other excellent case finishes showcased in the new Insignia™ Workbook. It was a complex open bite treated without debonds or wire bends, the signature of a Straight-Wire™ result. Insignia represents Ormco's commitment to digital orthodontics and now features CBCT-generated TruRoot™ data integration, improved Approver™ functionality and a wide range of scanner data acceptance.

In the back of this issue, you'll find a list of featured global CE events. In partnership with our orthodontic educators, mentors and industry specialists, Ormco is pleased to host over 750 educational events in 2017. Including new "practice performance" courses and a new Global Education Mobile App, Ormco's diverse educational program offers the latest in clinical and practice management insights.

On behalf of all of us at Ormco, thank you for partnering with us as we diligently work to support your clinical and practice success.

Best regards,

Patrik Eriksson
President, Ormco Corporation



A Practical Treatment Objective: Alveolar Bone Modeling with a Fixed, Continuous-Arch Appliance

Thomas W. Barron, D.M.D., M.S.

Frank Bogdan, D.M.D.

Frank Bogdan, D.M.D.

Bayonne, NJ, USA

In the private practice of orthodontics with his son Dr. Mark Bogdan, Dr. Bogdan is also an assistant clinical professor in the Department of Orthodontics at Rutgers University. He is also a member of the Ormco speaker's bureau.

Thomas W. Barron, D.M.D., M.S.

Timonium, MD, USA

In the private practice of orthodontics, Dr. Barron is also a member of the Dean's Faculty and an assistant clinical professor in the Department of Orthodontics at the University of Maryland School of Dental Medicine. He is a member of the Ormco speaker's bureau.

Bone is a dynamic tissue that is continuously adapting its structure via the processes of remodeling and modeling. *Remodeling* is the coupled sequence of resorption and formation involved in physiologic turnover. It is necessary to adjust internal architecture in response to mechanical needs, repair microdamages in the bone matrix, and to maintain plasma calcium homeostasis. Remodeling can only be observed *histologically* or by chemical assay of biomarkers. *Modeling* is a change in the size and shape of a bone that can be observed and measured *radiographically*. It is the net gross anatomic result of bone resorption and formation on a given bone surface in response to growth and development or mechanical load. These processes are well-accepted phenomena in the field of physiology.

In the orthodontic literature, it is widely held that the alveolar bones of the maxilla and mandible are immutable—that once formed, their size and shape cannot be changed significantly with tooth-borne, continuous-arch orthodontic appliances. Attempts to do so have been associated with root and cortical plate resorption, loss of periodontal attachment and unstable tipping of teeth.¹⁻⁴ Under this paradigm, orthodontic treatment must maintain the existing size and shape of the alveolar bone. In many cases, this can only be accomplished with surgery, tooth extraction, or separation of the mid-palatal suture.

In recent years, there has been a growing body of clinical evidence bolstered by studies that challenge the immutability of the alveolar bone and the mandate to treat to the existing dentoalveolar arch form.

The purpose of this article is to present a review of the literature challenging alveolar bone immutability along with clinical cases treated with passive self-ligating orthodontic brackets and low-friction/low-force protocols that demonstrate alveolar bone modeling.

Challenging Alveolar Bone Immutability

The alveolar process is defined as that part of the maxilla and mandible that forms and supports the sockets of the teeth (*Fig. 1*). It includes the thin lamella of bone that surrounds the root of the tooth and gives attachment to the principal fibers of the periodontal ligament.

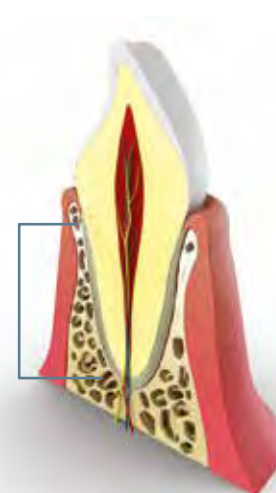

Figure 1.
Alveolar Process

It also includes the supporting inner and outer cortical plates of compact bone along with the spongy bone between the cortical plates.⁵ Though anatomically, no distinct boundary exists between the body of the maxilla or the mandible and their respective alveolar processes, the bone surrounding the teeth from root apex to the crest of the socket is considered to be the alveolar bone.⁶

By means of the teeth, alveolar bone can be loaded with biomechanical force. The cellular response of the PDL to orthodontic force has been well characterized on both the pressure and tension sides of the bony socket surrounding the root as the tooth and its periodontal ligament are translated through the trough of bone confined by the buccal and lingual cortical plates.⁷⁻¹⁰ Until recently, modeling—or changing the size and shape of the developed alveolus by translating the cortical plate—was not deemed possible with fixed orthodontic appliances, and consequently, has not undergone rigorous study. The critical questions that must be answered to challenge alveolar bone immutability and foster an acceptance of treatment modalities that are not confined to the existing size and shape of the alveolus are:

1. Is the alveolus, confined by the buccal and lingual cortical plates, immutable or is there evidence that it can undergo modeling?
2. If it can undergo modeling, under what conditions can it occur?
3. Can fixed, continuous-arch orthodontic appliances induce alveolar bone modeling?
4. Is there a cellular mechanism of action that can explain orthodontic-induced alveolar bone modeling?

Myo-Periosteal Induction of Alveolar Bone Modeling

Dr. Rolf Frankel described the transverse alveolar modeling observed in periadolescent patients treated with his Function Regulator Appliance (*Fig. 2*).¹¹⁻¹³ He reported that the increase in the transverse dimension observed in these patients is achieved primarily through the action of the buccal shields on the appliance. The acrylic shields disrupt the equilibrium of forces acting on the dentoalveolus by removing the pressure of the buccal musculature and allowing the light continuous force of the tongue to dominate. According to Frankel, when the forces of the cheeks are eliminated, the teeth tip laterally in the direction of least resistance. The alveolar walls in the radicular area are likewise deformed in a buccal direction.

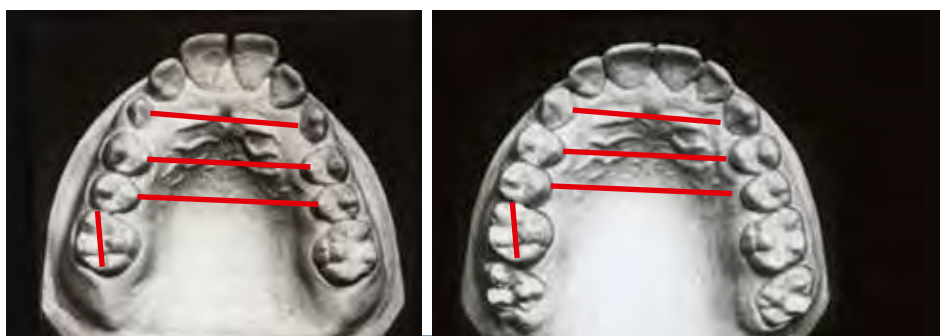

Figure 2. Typical transverse alveolar modeling observed in response to treatment with the Frankel Function Regulator. Pretreatment study model shown on the left and posttreatment on the right, size-corrected and marked for transverse development.

Furthermore, the acrylic shields extending into the vestibule exert a constant outward pull on the connective tissue fibers and muscle attachments that is transmitted to the alveolar bone by the fibers of the periosteum. Apposition of buccal bone aids in the lateral movement of the dentoalveolus. The ability of periosteal tension to induce apposition of bone on the lateral alveolus has been demonstrated in the animal studies of Altmann¹⁴⁻¹⁶ and Harvold.^{17,18} In addition, a study by Breiden, et al.,¹⁹ utilizing metallic implants placed in the maxillae of patients treated with the Frankel appliance demonstrated that widening of the maxilla was due to deposition of new bone along the lateral border of the alveolus rather than increased growth at the midpalatal suture.

This phenomenon of alveolar modeling, specifically lateral translation of the alveolus, achieved by disrupting the equilibrium of the inner and outer oral musculature and

periosteal tension is consistent with the Functional Matrix Theory of Moss.²⁰⁻²² While granting the innate growth potential of cartilage and bone, his theory holds that growth of the face occurs as a response to functional needs and neuromuscular influences and is mediated by the soft tissue in which the jaws are embedded. The theory, simply stated, is that bones do not grow but are grown, emphasizing the ontogenetic primacy of function over form. The Frankel appliance achieves a change in form by changing the function of the matrix tissues of the orofacial musculature.

Load-Induced Alveolar Bone Modeling

It is commonly observed in the field of dental medicine that the continuous load of a growing odontogenic cyst can significantly model the alveolar bone of the maxilla and mandible, causing remarkable displacement of the cortical bone.²³ This pathologic process is well established and has been extensively documented in case reports and textbooks. The interstitial pressure of various odontogenic cysts have been measured²⁴ and found to exert an ultra-low force load on the alveolar bone. This phenomenon clearly demonstrates that the developed alveolus can be modeled via pathologic induction with light, continuous force. Another commonly observed example of bone modeling is the bulge of the cortical plate associated with a palatally impacted canine. The impacted tooth is typically associated with an enlarged follicle. When the canine is exposed and brought into the center of the alveolus, a normal palatal contour returns.

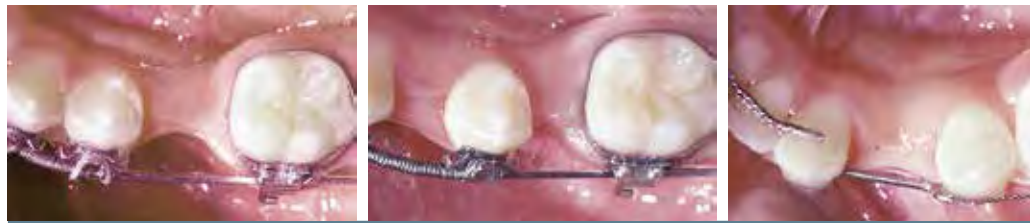

Figure 3. From Kokich, G., Kokich, V.: Congenitally missing mandibular second premolars: clinical options *Am. J. Orthod.* 130:437, 2006.

Kokich and Kokich²⁵ demonstrated localized modeling of the adult alveolus in response to tooth displacement. Light, continuous orthodontic force was employed to distalize a tooth into the atrophic alveolar ridge associated with a congenitally absent second premolar. The distalized tooth moved with its supporting bone, changing the size and shape of the atrophic alveolus (*Fig. 3*).

Fontenelle reported alveolar bone modeling with a passive/active dissociation appliance in non-growing patients.²⁶ The appliance (*Fig. 4*) consisted of a passive, rigid-cast lingual arch and active, low-modulus wires activated between the cast lingual arches. Dissociation of the passive and active components facilitates the application of low, constant-force load with near-constant moment-to-force ratios, resulting in bone modeling induced by dental displacement. Clinical cases were shown demonstrating lateral modeling of the alveolus as observed by Frankel and localized alveolar modeling with tooth displacement as observed by Kokich and Kokich.

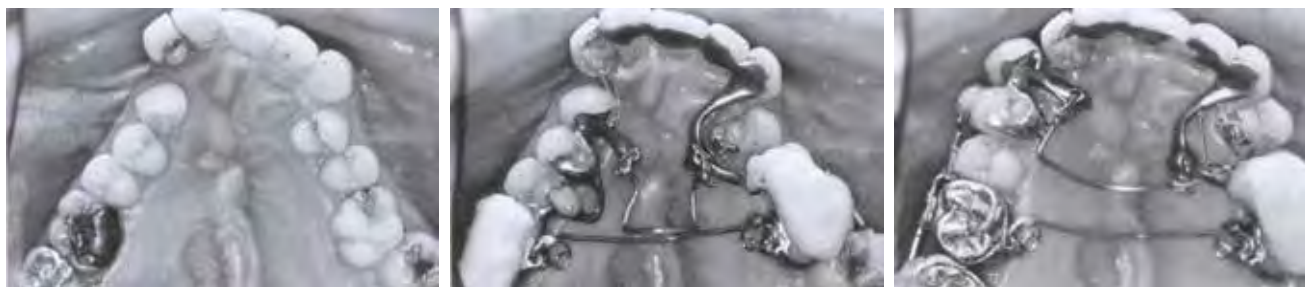

Figure 4. Alveolar bone modeling with the low load, constant force Passive/Active Dissociation Appliance described by Fontenelle. From Fontenelle, A: *Challenging The Boundaries of Orthodontic Tooth Movement in Orthodontics for the Next Millennium*, ed., R. Sachdeva, H.P. Bantleon, L. White, J. Johnson, ORMCO Glendora 1997, pp. 248-267

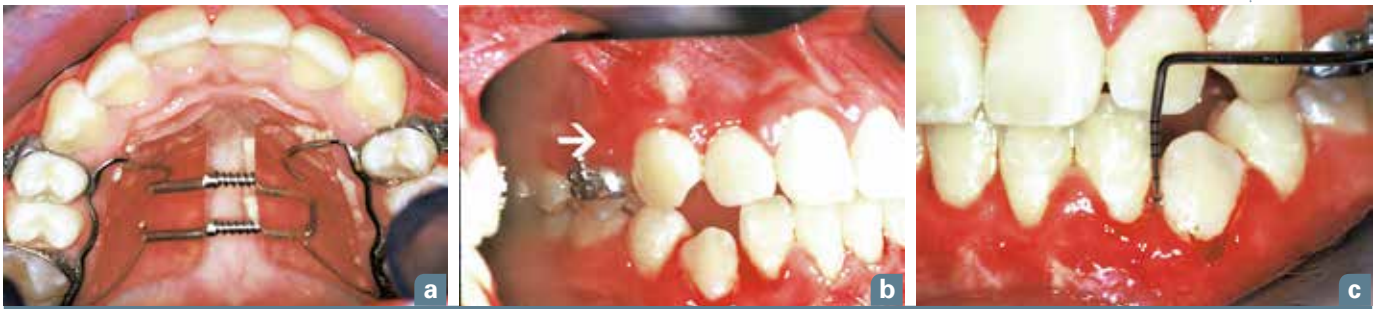

Figure 5a-c. From Williams, M.O., Murphy, N.C., *Beyond the ligament: a whole bone periodontal view of dentofacial orthopedics and falsification of universal alveolar immutability*, *Semin Orthod* 14:246, 2008.

Williams and Murphy described alveolar bone modeling with evidence of apposition of bone on the maxillary buccal alveolus in permanent dentition patients (*Fig. 5a-c*).²⁷ This was induced by a light, continuous load applied bilaterally to the maxillary alveolus with the Max 2000® alveolar development appliance (*Fig. 5a*).^{*} Their appliance consists of two nickel-titanium springs embedded in and connecting separate acrylic panels in a framework retained by bands on the first bicuspids and first molars. The transpalatal springs delivered 150 grams of force each in a lateral direction. Biopsies were performed on two patients upon

completion of lateral alveolar development. The specimens were harvested via full-thickness flaps from the labial alveolar crest between the maxillary right first bicuspid and canine (*Fig. 5b*). An internal control specimen was taken from interseptal bone between the ipsilateral mandibular first bicuspid and canine (*Fig 5c*). Standard hematoxylin and eosin stained sections were examined with and without polarized light and a maxillary specimen was subjected to fractional analysis.

The maxillary treatment sections demonstrated the absence of the lamellar pattern characteristic of mature bone and polarized light demonstrated a woven bone pattern characteristic of immature or new bone (*Fig. 6*). In addition, fractional analysis of the polarized light specimen demonstrated fractal patterns suggestive of woven bone modeling.

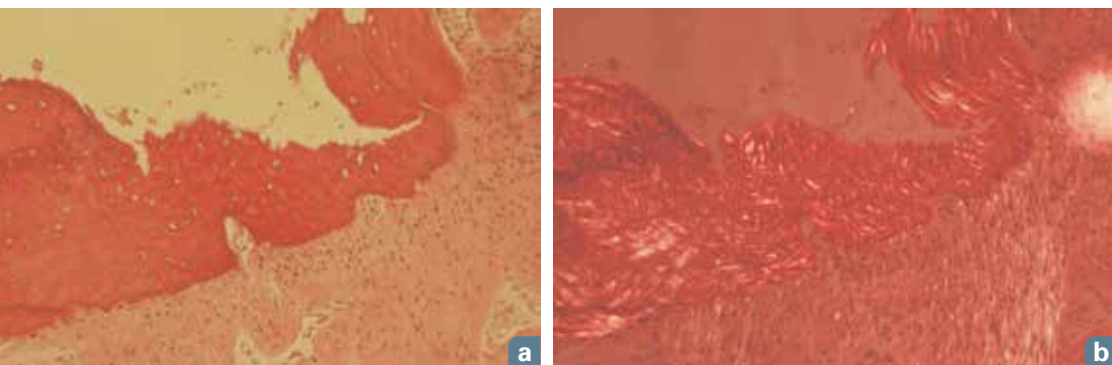


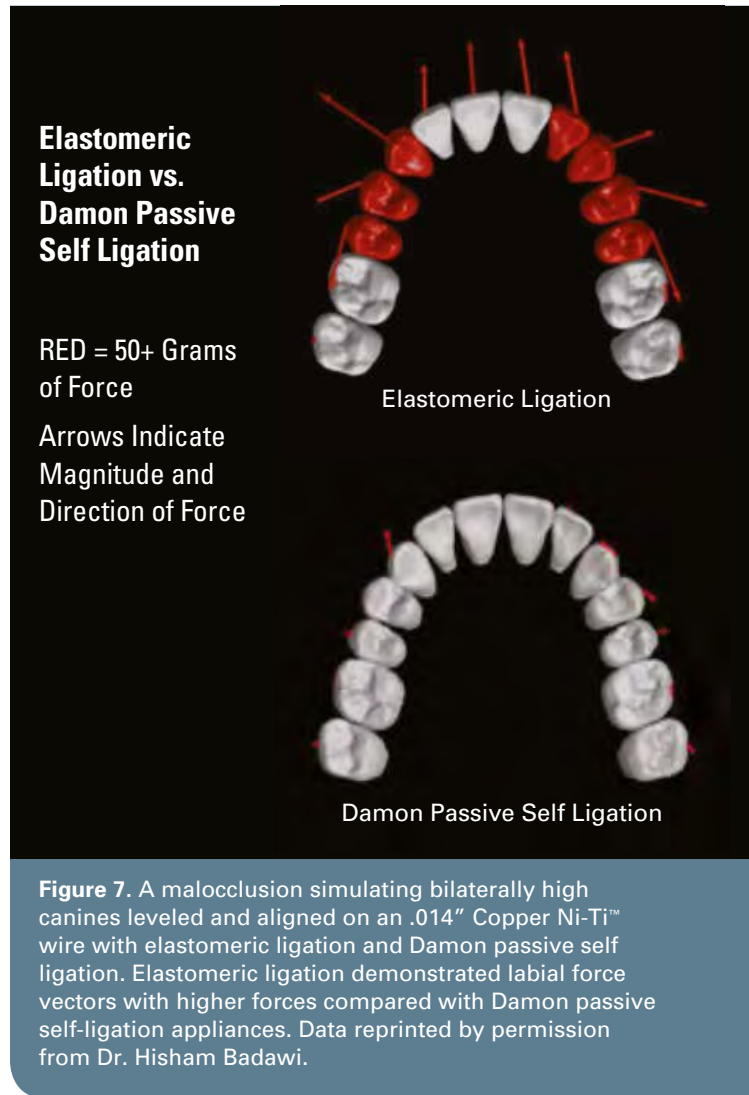
Figure 6a-b. Routine hematoxylin and eosin histological section at buccal aspect of tooth #5, labial to Max 2000 palatal alveolus development appliance. Note absence of a “lamellar” pattern that is characteristic of mature bone (a). A polarized light section of specimen. Note “woven bone” pattern characteristic of immature bone (b). From Williams, M.O., Murphy, N.C.: *Beyond the ligament: a whole bone periodontal view of dentofacial orthopedics and falsification of universal alveolar immutability*, *Semin. Orthod.* 14:246, 2008.

^{*}Max 2000 is a registered trademark of Dr. Michael O. Williams, Gulfport MS, produced by Dynaflex Orthodontic Laboratory, St. Louis, MO.

Alveolar Bone Modeling with a Fixed, Continuous-Arch Appliance

In recent years, fixed, passive self-ligating (PSL) appliances have been developed along with low-friction/low-force, continuous-arch protocols for orthodontic treatment. Dr. Hisham Badawi has reported evidence²⁸ with his OSIM apparatus²⁹ supporting the ability of passive self-ligating brackets to deliver lower-magnitude forces compared with elastomeric-ligated appliances applied to the same malocclusion in an in vitro model (Fig. 7). Evidence has also been reported supporting the ability of passive self-ligating brackets to achieve a reduction in the frictional resistance to sliding at the bracket/wire interface.^{30,31,32} The resultant load applied to the teeth and transmitted to the alveolar bone necessarily decreases as the frictional resistance to sliding and the force required to overcome it decreases. Clinical evidence has been reported demonstrating significant widening of the dental arches following treatment with the low-friction/low-force Damon™ System.^{33,34,35} An increase in the transverse dimension of the alveolar bone has also been reported in response to the low, biomechanical load delivered by this treatment regimen.^{36,37}

The following case reports provide examples of the alveolar bone modeling the authors have observed over a combined 28 years of experience utilizing the Damon passive self-ligating fixed appliance and treatment protocols advocated by Dr. Dwight Damon.



CHILD ALVEOLAR MODELING

Diagnosis

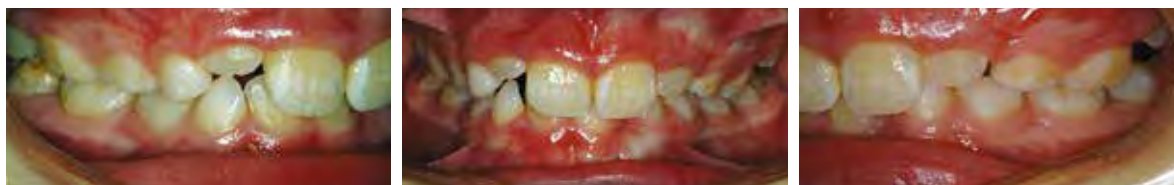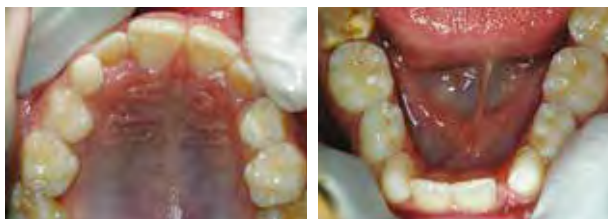
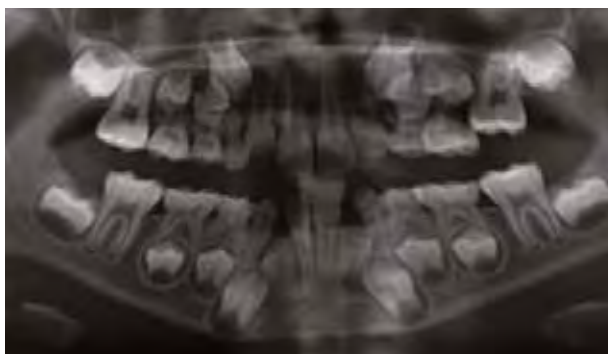
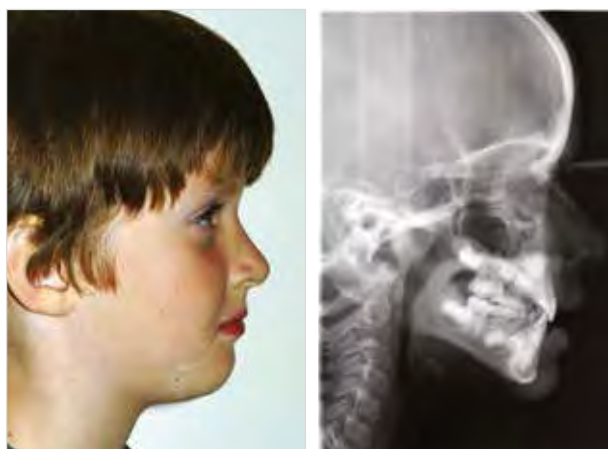
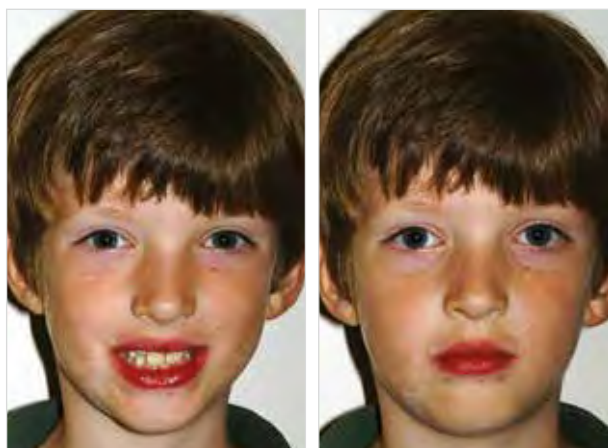A 9-year-old male patient presented in the mixed dentition with premature loss of his maxillary left primary canine with space loss and a blocked-out, unerupted permanent canine. His mandibular arch presented with severe crowding and completely blocked-out and unerupted lateral incisors. He exhibited normal circumoral muscle tonus and lip competence. The lateral ceph showed upright maxillary and mandibular incisors.

Treatment Summary

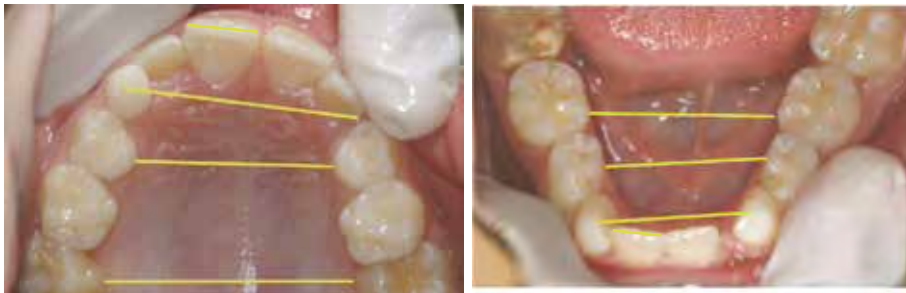Phase I mixed-dentition treatment was initiated with Damon passive self-ligating appliances, including brackets placed on all the non-mobile primary teeth. Copper Ni-Ti wires (.014") and light NiTi coil springs were activated one-half-of-a-bracket length between the mandibular permanent central incisors and primary canines, and between the maxillary left permanent lateral incisor and primary first molar. Low-torque brackets were selected for the upper and lower incisors to help minimize proclination from the force of the spring. Damon wire sequence protocols were observed.

Result

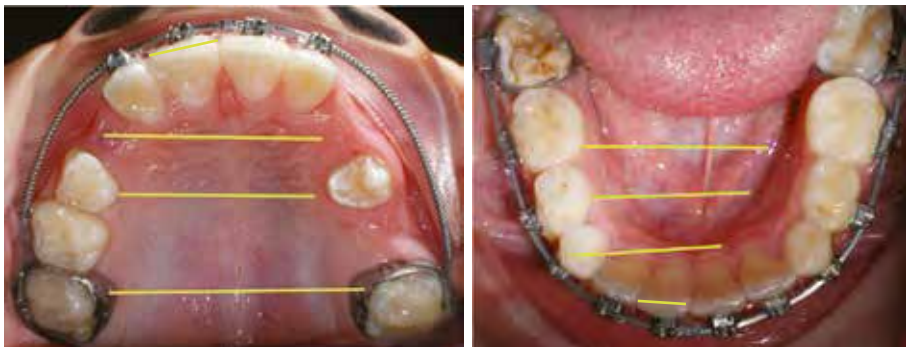Pre- and posttreatment images demonstrate the treatment result after 16 months of treatment. The size-corrected view of the mandibular arch illustrates the significant change in the size and shape of the mandibular alveolar bone induced by this approach. Similar changes were seen in the maxilla as well. The patient's parents were pleased with the result of Phase I treatment and opted not to pursue Phase II finishing treatment.



CHILD ALVEOLAR MODELING: Pre-/Posttreatment Comparison Demonstrates Alveolar Bone Modeling

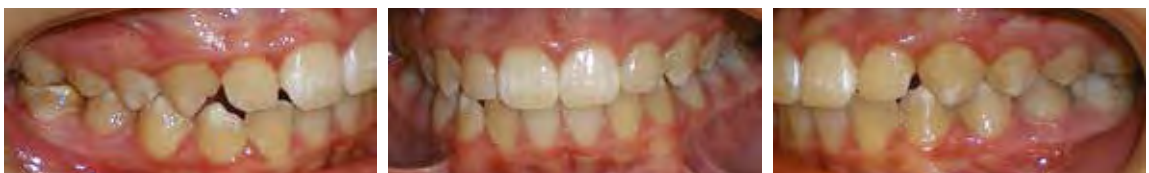
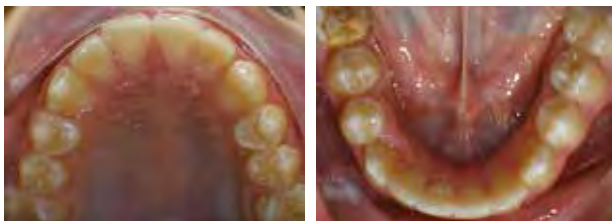
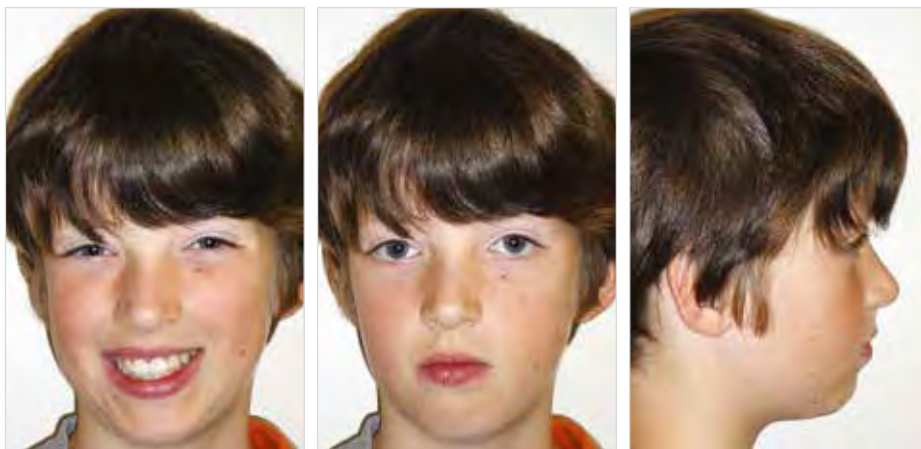PRETREATMENT



POSTTREATMENT

CHILD ALVEOLAR MODELING: AFTER ERUPTION OF PERMANENT TEETH. PHASE II TREATMENT WAS NOT PURSUED IN THIS CASE



PERIADOLESCENT ALVEOLAR MODELING

Diagnosis

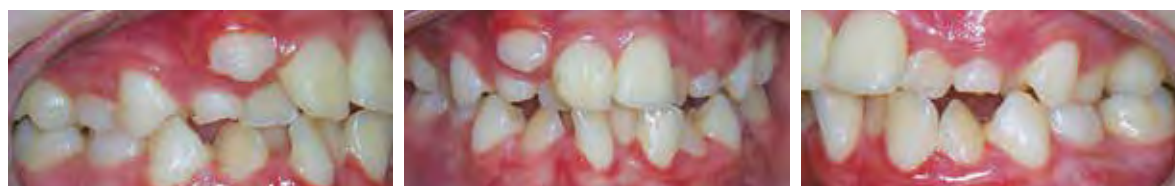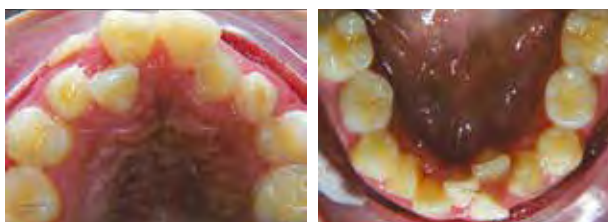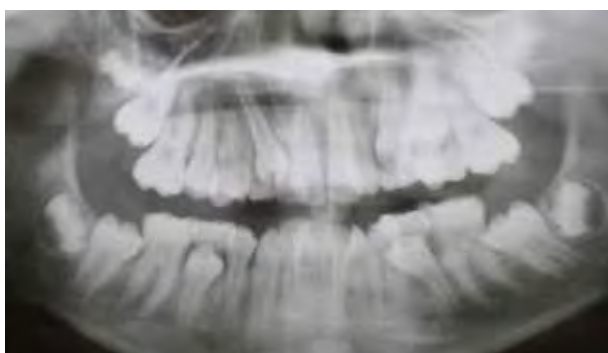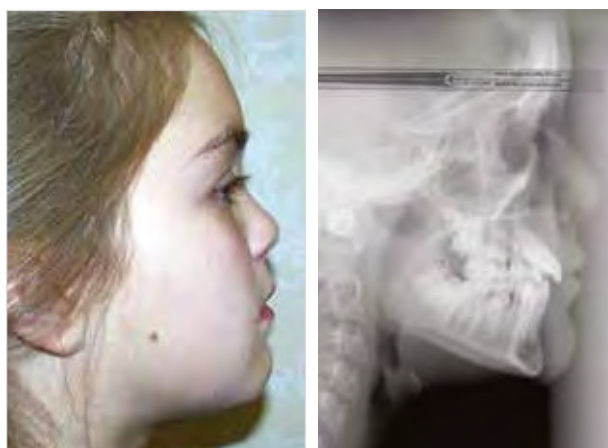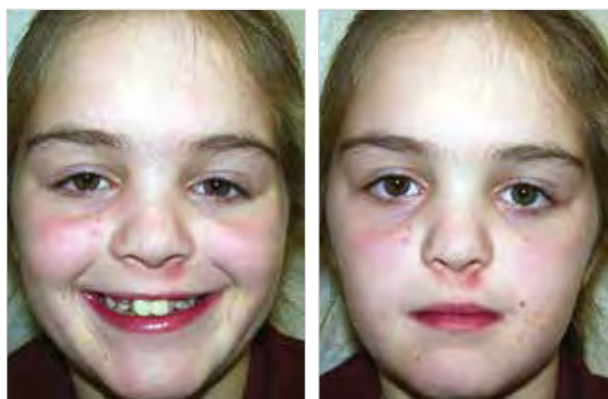An 11.5-year-old female patient presented with a Class I jaw relationship and severe tooth size/arch length discrepancies with 9 mm of crowding in the maxillary arch and 15 mm of crowding in the mandibular arch. Her mandibular incisors were upright at 89° to the mandibular plane and she exhibited normal circumoral muscle tonus and competent lips. Her parents wanted to attempt a nonextraction treatment plan. Informed consent was obtained and a therapeutic diagnosis was initiated with a reassessment planned for approximately 6 to 9 months to determine if the nonextraction attempt could continue or if extraction would be required.

Treatment Summary

Damon protocols were employed with initial .013" Copper Ni-Ti wires and NiTi open-coil springs activated one-half-of-a-bracket width to begin to create space for the unbracketed, blocked-out teeth. Eyelet attachments were placed on the lingually blocked-out teeth and lightly ligated to the coil springs with enough force to minimally deflect the archwire.

Since the alignment at the 10-week appointment was deemed insufficient to engage a larger wire and comfortably close the bracket door, the initial wires were inspected for deformation and replaced. The springs were then reactivated, the blocked teeth religated and the patient reappointed for 8 weeks.

Although in significantly crowded cases the transitional wire is typically a .018" Copper



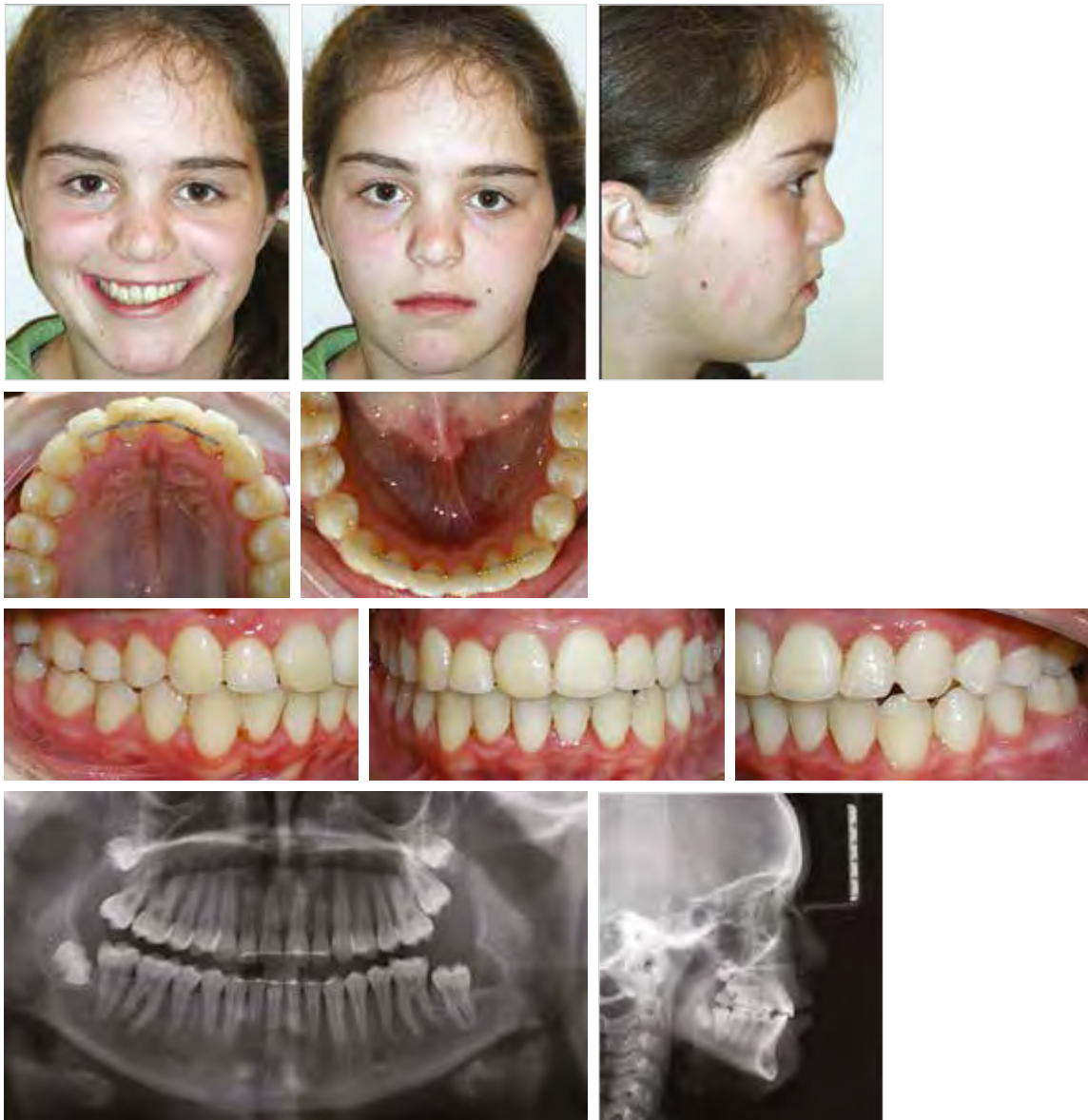Ni-Ti wire engaged in preparation for a .014" x .025" Copper Ni-Ti wire, at the 18th week bracket alignment was again deemed insufficient for rectangular wire engagement so a .014" Copper Ni-Ti wire was placed, the springs were reactivated and the blocked-out teeth religated.

At subsequent appointments as space was created, initially blocked-out teeth were bracketed and engaged with .014" Copper Ni-Ti wires. At 8.5 months, the decision was made to continue with the nonextraction treatment plan. This severely crowded case did not progress beyond the .018" Copper Ni-Ti wires until 12 months into treatment.

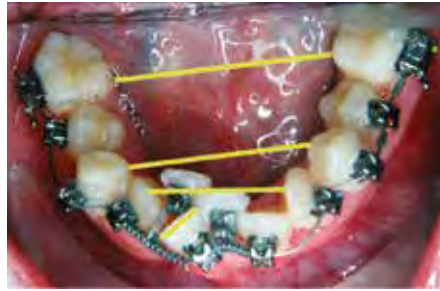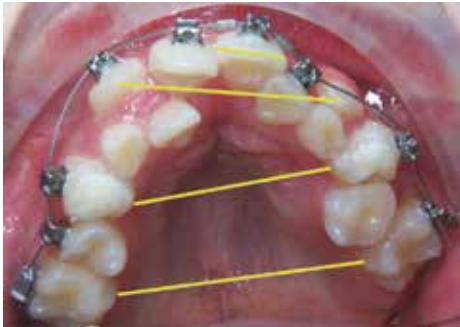Results

The final result was obtained after 23 months of treatment. Retention included bonded lingual wire retainers and clear, vacuum-formed Essex-style removable retainers to be worn while sleeping. Size-corrected lower occlusal photographs taken at initial bonding and debonding illustrate the change in the size and shape of the mandibular alveolus induced by passive self-ligation treatment. By the three-year posttreatment followup appointment, teeth #8 and #9 had been crowned and the bonded maxillary lingual wire had been removed. The patient reported infrequent removable retainer wear and the alveolar modeling obtained had remained remarkably stable.

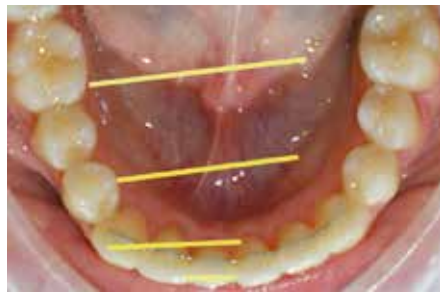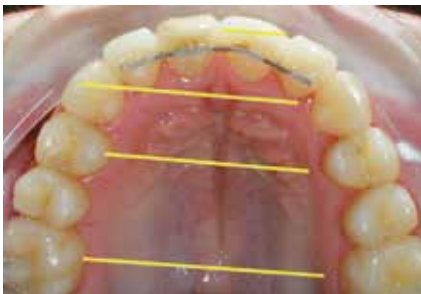PERIADOLESCENT ALVEOLAR MODELING: RESULTS



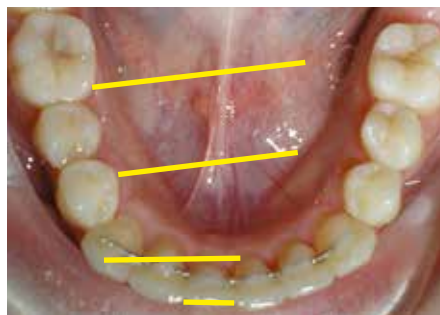
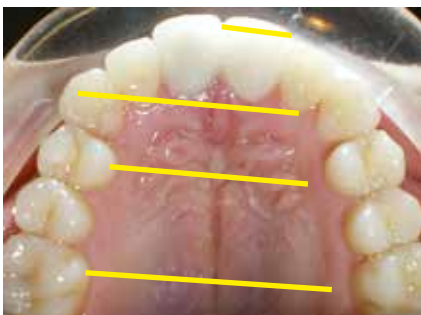PERIADOLESCENT ALVEOLAR MODELING: Pre-/Posttreatment Comparison Demonstrates Alveolar Modeling



PRETREATMENT



POSTTREATMENT



**3 YEARS
POSTTREATMENT**

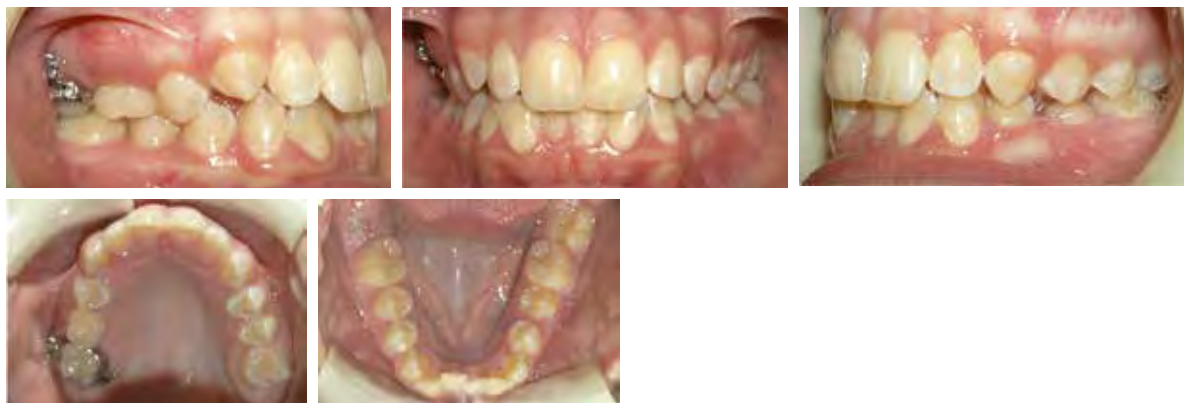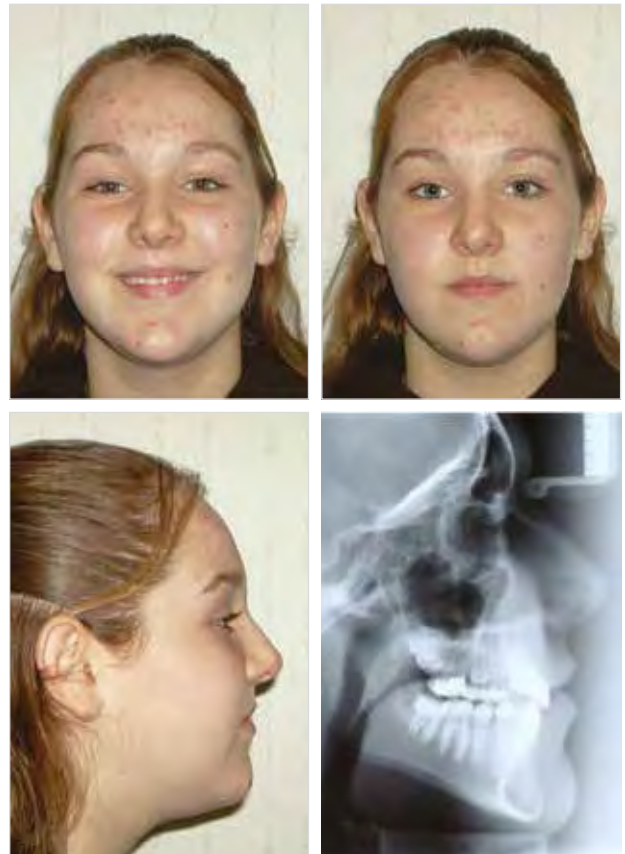ADOLESCENT ALVEOLAR MODELING

Diagnosis

A female patient age 13 years, 5 months presented with a Class I malocclusion, crowding and constricted dental arches. Her case illustrates how muscular imbalance can have a constricting impact on the development of dentoalveolar bone. The collapsed buccal segments and retroclined mandibular incisors are indicative of the influence of hypertonic buccinator and orbicularis oris muscles.

Treatment Summary

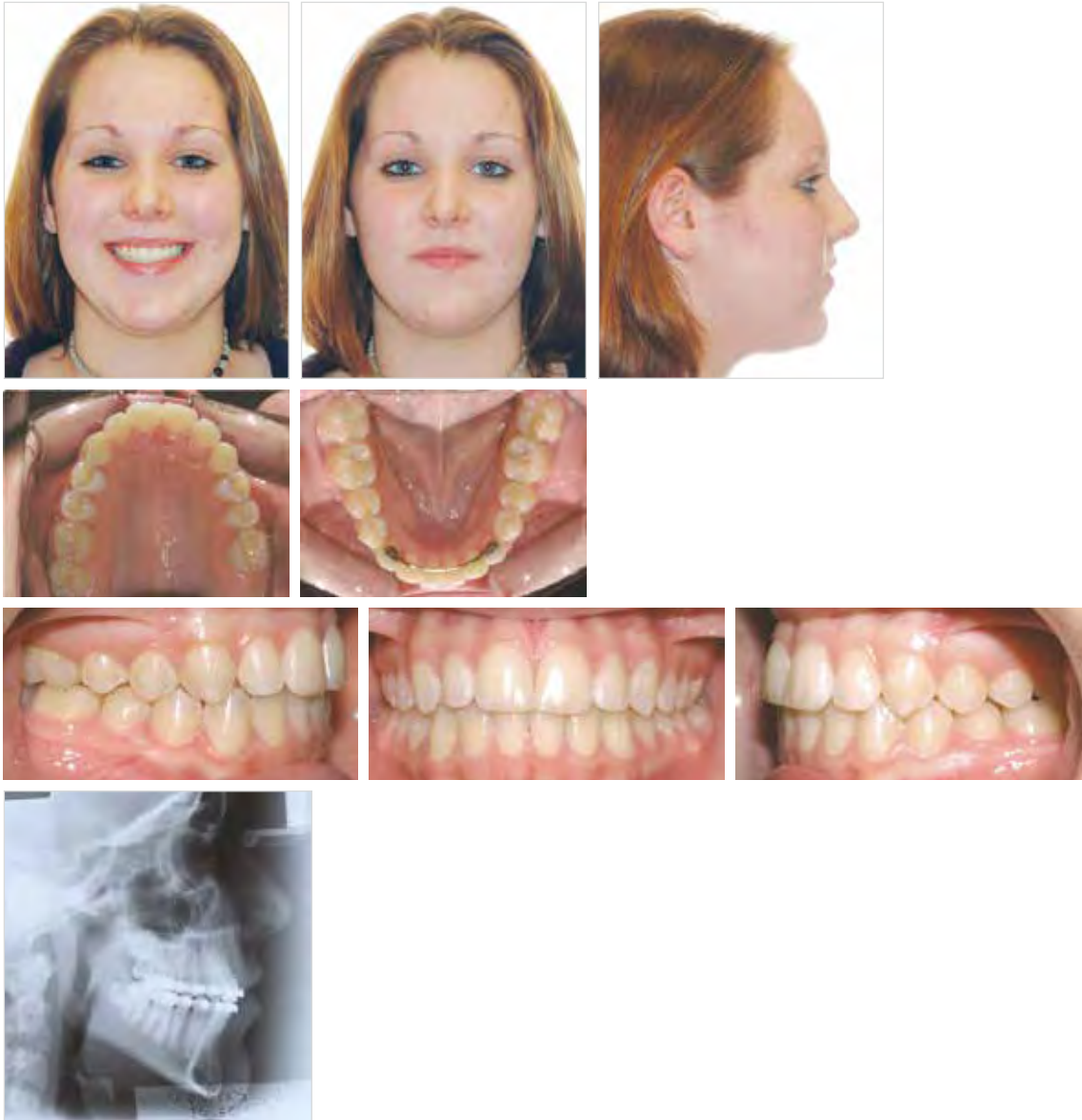The key element in cases like this are the leveling sequence and the use of turbos for disarticulation. It is essential to stay in round wires at least 6 months to give the muscles adequate time to rebalance; that is, to change the balance of forces between the overpowered tongue muscle versus the muscles of the lips and cheeks. With passive self-ligation, muscles become an ally in treatment similar to the way the Frankel assists transverse development. The wire sequence in this case (both arches) was .013", .016" and .018" (6.5 months) Copper Ni-Ti followed by .014" x .025" and .018" x .025" Copper Ni-Ti (8 weeks each). The case was finished in .019" x .025" TMA (upper) and .017" x .025" TMA (lower).



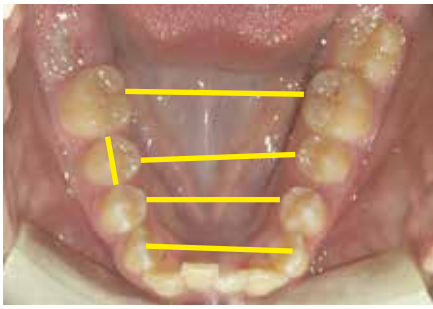
ADOLESCENT ALVEOLAR MODELING: RESULTS

Results

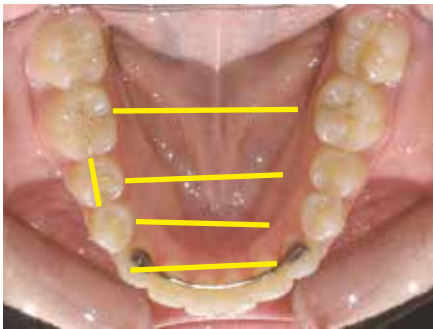
The case result was obtained in 19 months. The light, biomechanical load transmitted to the alveolar bone with a fixed, PSL appliance combined with small diameter, low-modulus-of-elasticity archwires demonstrates alveolar bone modeling as the teeth uprighted in the transverse dimension of the patient's mandibular arch.



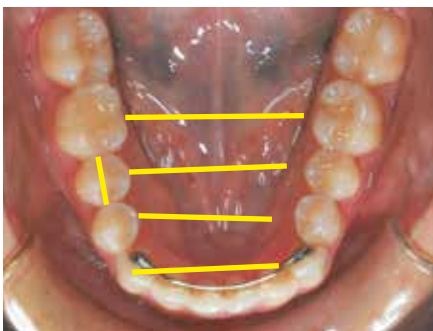
ADOLESCENT ALVEOLAR MODELING: PRE-/POSTTREATMENT COMPARISON DEMONSTRATES ESTHETIC BENEFIT OF TRANSVERSE ALVEOLAR BONE MODELING



PRETREATMENT



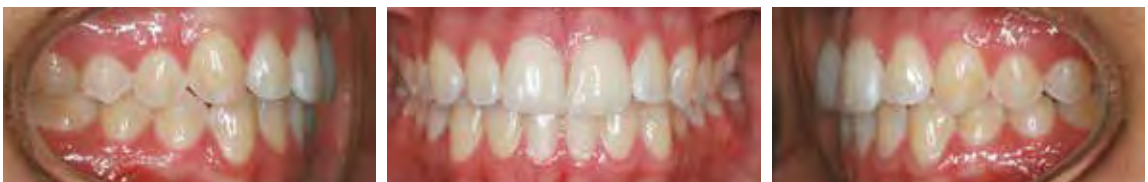
POSTTREATMENT



**6.5 YEARS
POSTTREATMENT**

Note: The mandibular canines in the patient's retention records seem to indicate significant expansion but is explained by the uprighting of these teeth over their apices.

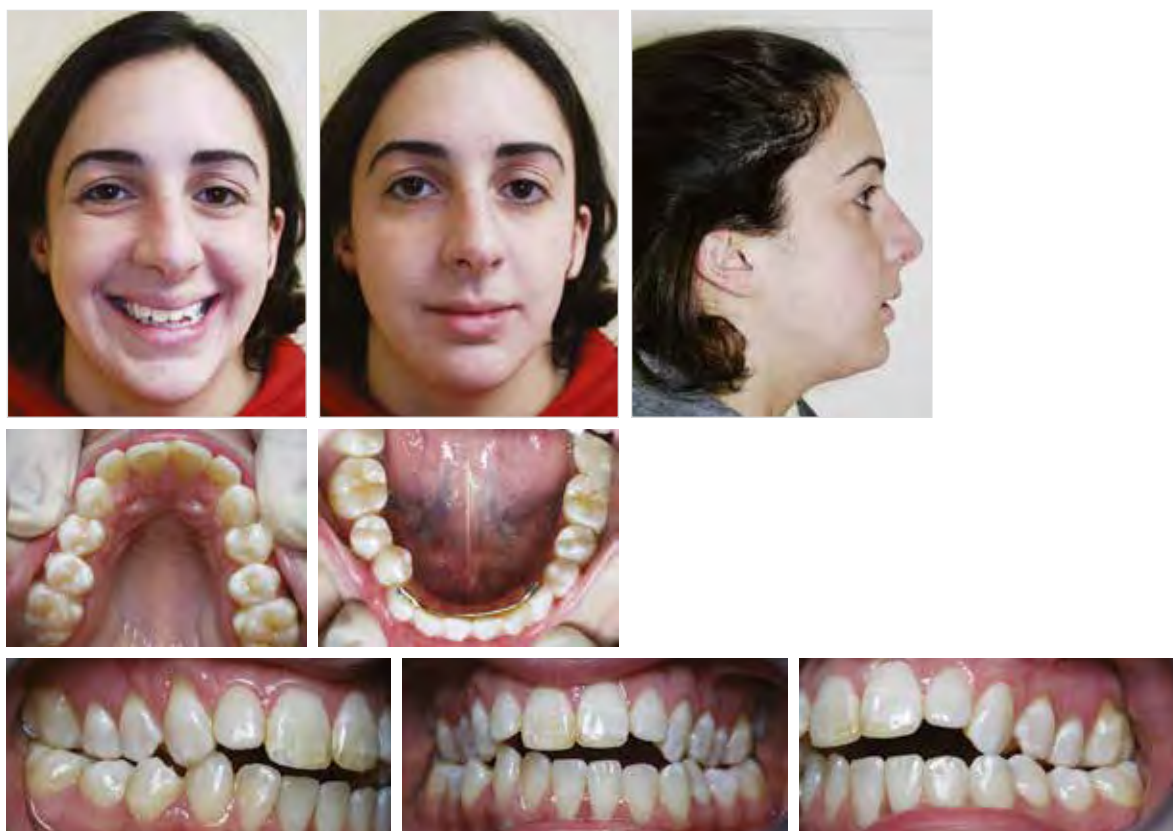ADOLESCENT ALVEOLAR MODELING: STABLE RESULTS 6.5 YEARS POSTTREATMENT



ADULT ALVEOLAR MODELING

Diagnosis

A 21-year-old female patient presented with an anterior open bite and bilateral, posterior cross bites. Her dental history included Phase I expansion and Phase II comprehensive treatment with another orthodontist. She was referred by an oral surgeon for orthodontic alignment prior to orthognathic surgery to correct the open bite and constricted maxilla.

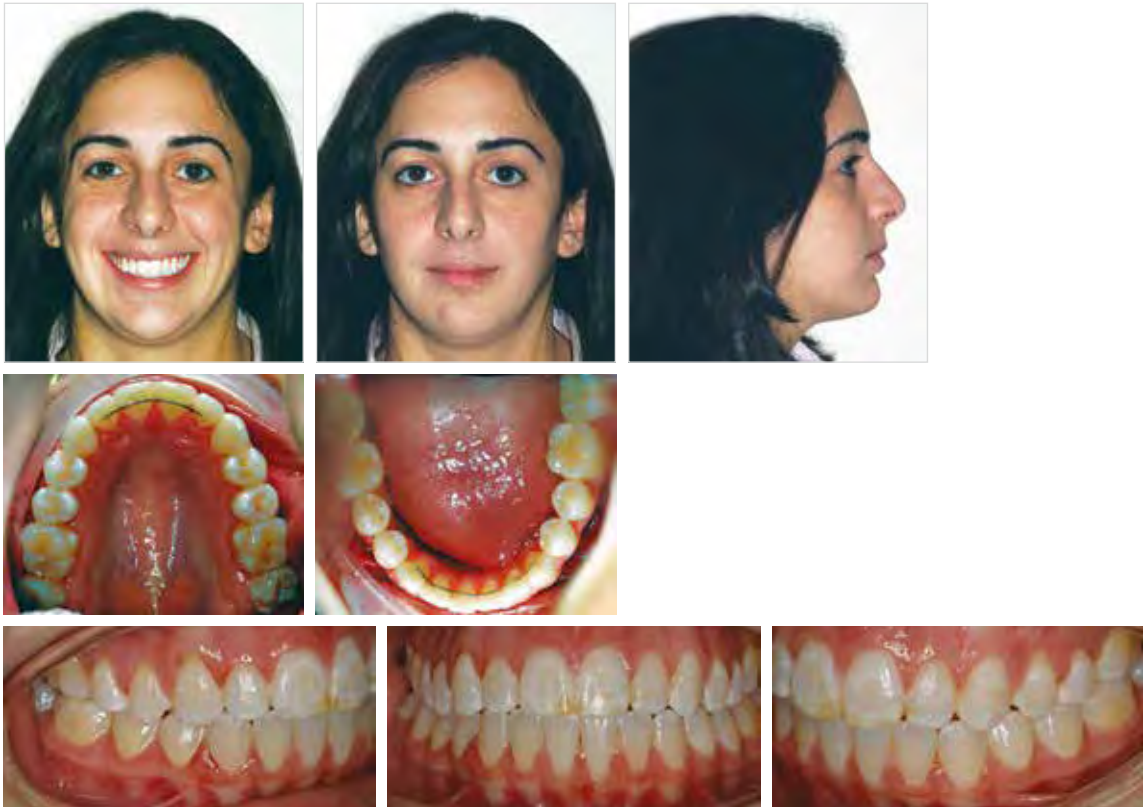

Treatment Summary

Treatment was initiated using PSL appliances and low-friction/low-force protocols with 2 oz. posterior cross elastics engaged bilaterally from attachments on the lingual surfaces of the maxillary second premolars and first molars to buccal attachments on the mandibular second premolars and first molars. The occlusion was disarticulated with flat-plane composite build-ups on the occlusal surfaces of the maxillary first and second molars.

When the case progressed to the .019" x .025" stainless steel wires, the maxillary arch was sectioned bilaterally between the lateral incisors and canines in preparation for surgery. The surgeon, however, deemed that orthognathic surgery was no longer required. The case was finished with vertical elastics and retained with bonded lingual retainers and a Damon Splint retainer prescribed for nightly wear for the initial 12 months of retention.

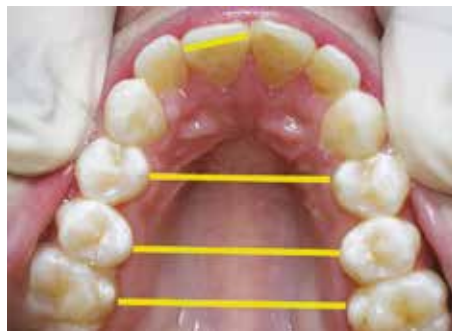ADULT ALVEOLAR MODELING: Results



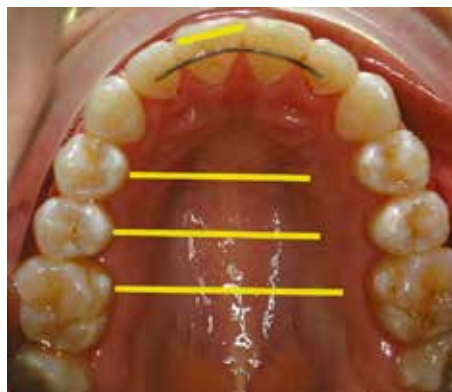ADULT ALVEOLAR MODELING: Pre-/Posttreatment Comparison Demonstrates Alveolar Modeling. Surgery was Precluded in this Case.

Results

Treatment was completed in 21 months. Size-corrected upper occlusal photographs taken at bonding and debonding illustrate the change in the size and shape of the maxillary alveolus induced by passive self-ligation treatment. Unfortunately, the patient relocated and was unavailable for long-term followup.



PRETREATMENT



POSTTREATMENT

Discussion

The case reports presented demonstrate examples of the change in the size and shape of the maxillary and mandibular alveolar bone observed in adolescent, adult and children treated with a passive self-ligating, continuous-arch appliance and Damon low-friction/low-force treatment protocols. Specifically, the increase in the transverse dimension of the alveolus appears to be the result of lateral translation of the buccal and lingual cortical plates induced by the biomechanical load applied to the teeth and transmitted to the alveolar bone. These cases provide additional clinical evidence for the ability of the alveolar bone to undergo biomechanical load-induced modeling.

As Frankel had done previously with his Function Regulator appliance, Damon has proposed a mechanism of action for the dentoalveolar response to his treatment regimen. Based on clinical observations and analysis of photographs, plaster study model measurements and medical CT surveys³⁶ of treated cases, he suggests that the light, continuous force delivered by his treatment approach disrupts the equilibrium of the tooth positions maintained by the inner and outer oral musculature acting on the alveolus and dentition. When the anterior component of the force acting along the continuous archwire is kept low, it is mitigated by the resting pressure of the lip³⁸ in patients with adequate circumoral muscle tonus. The posterior component of force is likewise resisted by multi-rooted molars along with the ascending ramus in the mandible and the tuberosity in the maxilla. A resultant lateral component of force is expressed and transmitted from the teeth to the alveolar bone, inducing bone modeling or posterior arch adaptation as he describes it.

The OSIM findings of Badawi support Damon's proposed mechanism of action, specifically the assertion of a lower anterior vector of force delivered with a passive self-ligating appliance compared with an elastomeric-ligated appliance applied to the same simulated malocclusion. In addition, there is a cellular mechanism of action that supports alveolar bone modeling induced

by tooth displacement. *Figure 8* from Graber describes bone modeling occurring in the periodontal ligament and on the periosteal surfaces resulting from net apposition of bone in the direction of the line of applied force and net resorption of bone away from the direction of force. Furthermore, this ability to move bone with a light, continuous load applied to the teeth has been corroborated in the sagittal dimension by Melsen^{39,40} and Allais.⁴¹

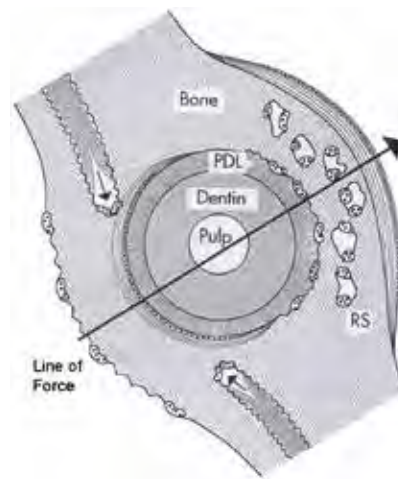


Figure 8. Orthodontic bone modeling, or site-specific formation and resorption, occurs along the periodontal ligament and periosteal surfaces. Illustration from *Orthodontics: Current Principles and Techniques*, Graber, Vanarsdall & Vig, 4th edition. Reprinted by permission.

Despite the evidence presented in this article, there remains considerable debate regarding the immutability of the alveolar bone and the treatment response to low-friction/low-force passive self-ligating appliances. Rigorous investigation should be undertaken to validate and understand these clinical observations. Future clinical investigations should incorporate case selection criteria that include subjects with adequate circumoral muscle tonus as well as close adherence to the established treatment protocols as described in the case reports above. In addition, future CBCT analysis should consider the voxel size and resolution of the machines used in making alveolar bone determinations as well as the time period in which the posttreatment assessments are undertaken to allow adequate time for completion of secondary mineralization.

Conclusions

This article presents case reports demonstrating a change in the size and shape of the alveolar bone in child, adolescent and adult patients treated by a continuous-arch, self-ligating appliance. These cases, along with a growing body of evidence, challenge the immutability of the alveolar bone and the axiom of treating to the existing arch form. It is the authors' considered opinion that Melvin Moss's Functional Matrix Theory is correct and the change in alveolar form induced by this low-friction, low-force treatment approach provides an opportunity to recapture the full genetic potential of the patient's alveolus. Furthermore, alveolar bone modeling is a practical treatment objective that can decrease the need for more invasive approaches in appropriately selected and appropriately treated patients.

Acknowledgment: The authors wish to acknowledge Dr. Rob Laraway, resident at the University of Maryland, Department of Orthodontics, for his assistance with the literature review for this article.

To download a copy of this article, go to ormco.com/cisummer2017.

References

- ¹ Andlin-Sobocki, A., Bodin, L.: Dimensional alterations of the gingiva related to changes of facial/lingual tooth position in permanent anterior teeth of children: a 2-year longitudinal study, *J. Clin. Periodontol* 20:219, 1993.
- ² Batenhorst, K., Bowers, G., Williams, J.: Tissue changes resulting from facial tipping and extrusion of incisors in monkeys, *J. Periodontol* 45:660, 1974.
- ³ Steiner, G., Pearson, J., Ainamo, J.: Changes of the marginal periodontium as a result of labial tooth movement in monkeys, *J. Periodontol* 52:314, 1981.
- ⁴ Brezniak, N., Wasserstein, A.: Root resorption after orthodontic treatment. Literature review, *Am. J. Orthod.* 103(62):138, 1993.
- ⁵ Orban's Oral Histology and Embryology, 10th ed., ed. S.N. Bhaskar, CV Mosby Co., St. Louis, 1986, pp. 236-238.
- ⁶ Glickman's Clinical Periodontology, 6th ed., ed. F.A. Carranza, WB Saunders Co., Philadelphia, 1984, pp. 51-58.
- ⁷ Reitan, K.: Tissue behavior during orthodontic tooth movement, *Am. J. Orthod.* 46:881, 1960.
- ⁸ Reitan, K.: Effects on force magnitude and direction of tooth movement on different alveolar bone types, *Angle Orthod.* 34: 244, 1964.
- ⁹ Rygh, P.: Ultrastructural cellular reactions in pressure zones of rat molar periodontium incident to orthodontic tooth movement, *Acta Odontol. Scand.* 30:575, 1973.
- ¹⁰ Rygh, P.: Ultrastructural changes in tension zones of rat molar periodontium incident to orthodontic tooth movement, *Am. J. Orthod.* 70:269, 1974.
- ¹¹ Frankel, R.: The theoretical concept underlying the treatment with function correctors, *European. Orthodontic Society*, 42:233, 1966.
- ¹² Frankel, R.: Decrowding during eruption under the screening influence of vestibular shields. *Am. J. Orthod.* 65:372-406, 1974.
- ¹³ *Removable Orthodontic Appliances*, 2nd ed., ed. T.M Graber, B. Neuman, WB Saunders Co., Philadelphia, 1984. pp. 563-565.
- ¹⁴ Altmann, K.: Experimentelle Untersuchungen über mechanische Ursachen der Knochenbildung, *Z. Anat. Entwicklungsgesch.* 114:457, 1949.
- ¹⁵ Altmann, K.: Untersuchungen über Frakturheilung unter besonderen experimentellen Bedingungen, *Z. Anat. Entwicklungsgesch.* 115:63, 1950.
- ¹⁶ Altmann, K.: Zur kausalen Histogenese des Knorpels, Berlin, 1964, Springer Verlag.
- ¹⁷ Harvold, E.P.: Neuromuscular and morphological adaptations in experimentally induced oral respiration. In: *Naso-Respiratory Function and Craniofacial Growth*. J.A. McNamara (ed.), Monograph 9, Craniofacial Growth Series, Center for Human Growth and Development, The university of Michigan, Ann Arbor, 1979.

- ¹⁸ Havold, E.P.: Altering craniofacial growth: force application and neuromuscular-bone interaction. In: *Clinical Alteration of the Growing Face*. J.A. McNamara, K.A. Ribbens, and R.P. Howe (eds.) Monograph 14, Craniofacial Growth Series, Center for Human Growth and Development, The university of Michigan, Ann Arbor, 1983.
- ¹⁹ Breiden, C.M., Pangrazio-Kulbersh, V., Kulbersh, R.: Maxillary skeletal and dental change with Frankel appliance therapy-an implant study. *Angle Orthod.* 54:232, 1984
- ²⁰ Moss, M.: *The functional matrix (Chapter) Vistas in orthodontics*, Philadelphia, 1962, Lea and Febiger.
- ²¹ Moss, M.: The role of the functional matrix in mandibular growth, *The Angle Orthodontist*, 38:(4) 95-103, 1968.
- ²² Frankel, R.: The practical meaning of the functional matrix in orthodontics, *Tran. Eur. Orthod. Soc.* 45: 207-219, 1969.
- ²² Frankel, R.: The theoretical concept underlying the treatment with function correctors, *European. Orthodontic Society*, 42:233, 1966.
- ²³ Damon, D.H.: Personal communication, November 2004.
- ²⁴ Kubota, Y., Yamashiro, T., Oka, S., Ninomiya, T., Ogata, S., Shirasuna, K.: Relation between size of odontogenic jaw cysts and the pressure of fluid within, *Brit. J. Oral and Maxillofacial Surg*, 42(5): 391, 2004.
- ²⁵ Kokich, G., Kokich, V.: Congenitally missing mandibular second premolars: clinical options, *Am. J. Orthod.* 130:437, 2006.
- ²⁶ Fontenelle, A.: Challenging the boundaries of orthodontic tooth movement in *Orthodontics for the Next Millennium*, ed., R. Sachdeva, H.P. Bantleon, L. White, J. Johnson, ORMCO, Glendora, 1997, pp. 248-267.
- ²⁷ Williams, M.O., Murphy, N.C.: Beyond the ligament: a whole bone periodontal view of dentofacial orthopedics and falsification of universal alveolar immutability, *Semin. Orthod.* 14:246, 2008.
- ²⁸ Badawi, H.: personal communication November 2012.
- ²⁸ Badawi, H.M., Toogood, R.W., Carey, J.P., Heo, G., Major, P.W.: Three-dimensional orthodontic force measurements. *Am. J. Orthod.* 136:(4) 518, 2009.
- ³⁰ Birnie, T.S., Sheriff, M.: A comparative in vitro study of the frictional characteristics of two types of self ligating brackets and two types of pre-adjusted edgewise brackets tied with elastomeric ligatures. *Eur. J. Orthod.* 20:589, 1998.
- ³¹ Pizzoni, L., Raunholt, G., Melsen, B.: Frictional forces related to self-ligating brackets. *Eur. J. Orthod.* 20:283, 1998.
- ³² Thorntenson, G.A., Kusy, R.P.: Comparison of resistance to sliding between different self-ligating brackets with second-order angulation in the dry and saliva states. *Am. J. Orthod.* 121:472, 2002.
- ³³ Lineberger, M.B., Franchi, L., Cevidane, L.H.S., Ghislanzoni, L.T.H., McNamara, J.A.: Three-dimensional digital cast analysis of the effects produced by a passive self-ligating system. *Eur. J. Orthod.* 609-614, 2016.
- ³⁴ Vajaria, R., BeGole, E., Kusnoto, B., Galang, M.T., Obrez, A.: Evaluation of incisor position and dental transverse dimensional changes using the Damon System. *Angle Orthodontist* 81, No 4, 647-652, 2011.
- ³⁵ Basciftci, F.A., Akin, M., Iler, Z., Bayram, S.: Long-term stability of dentoalveolar, skeletal and soft tissue changes after non-extraction treatment with a self-ligating system. *Korean J. of Orthod.* 44(3):119-127, 2014.
- ³⁶ Damon, D.H.: Treatment of the face with biocompatible orthodontics in *Orthodontics: Current Principles & Techniques*, 4th ed., ed. T.M. Graber, R.L. Vanarsdall, K.W.L. Vig, Elsevier, Inc, Philadelphia, 2005, pp. 753-831.
- ³⁷ Birnie, D.: The Damon passive self-ligating appliance system, *Semin. Orthod.* 14:19, 2008.
- ³⁸ Moawad, S., et. al.: Lip adaptation to simulated dental arch expansion Part 2: One week of simulated expansion, *The Angle Orthodontist*, 66(4):255-260, 1996.
- ³⁹ Melsen, B.: Master Clinician: Birte Melsen, *J. Clin. Orthod*, 47(10):581-594, 2013.
- ⁴⁰ Melsen, B., Allais, D.: Factors of importance for the development of dehiscences during labial movement of mandibular incisors: A retrospective study of adult orthodontic patients, *Am. J. Orthod.* 127:552-561, 2005.
- ⁴¹ Allais, D., Melsen, B.: Does labial movement of lower incisors influence the level of the gingival margin? A case control study of adult orthodontic patients, *Eur. J. Orthod.* 25: 343-352, 2003.

Ormco[™]

Your Practice. Our Priority.



Featured Damon patients treated by
Drs. Todd Bovenizer and Stuart Frost.

THE CLEAR APPLIANCE FOR **ALL** YOUR PATIENTS

Efficiently treat *all* your patients to a beautiful result with the improved **Damon Clear2** bracket that provides the control needed for you to treat a wide variety of cases with outstanding results.



Adult Open Bite Case



Adult Impacted Cuspid Case



Visit ormco.com/damon to learn more.

DAMON[™] CLEAR2

CASE STUDY:

Insignia™ Resolves Adult Open Bite with Straight-Wire™ Finishing

Dr. David González Zamora, Madrid, Spain



In January 2017, Ormco released the Insignia Workbook, a collection of best practices and case reviews from experienced Insignia users around the globe. The workbook also takes a look at Insignia’s development over the years and explains the science behind this pioneering product. The following case study from Dr. David González Zamora, Madrid, Spain, is excerpted from the workbook.

To download your digital copy of the new Insignia Workbook, visit ormco.com/cisummer2017.

Pretreatment Diagnosis

Adult female, mesofacial, skeletal class I, open bite. Patient suffered from frequent headaches.

Treatment Plan Objectives

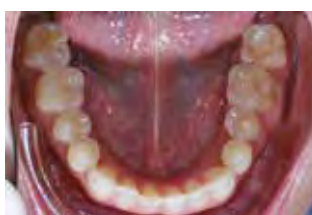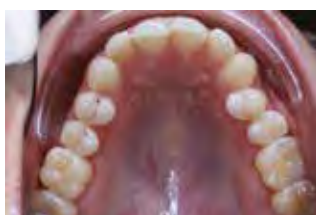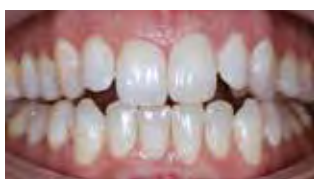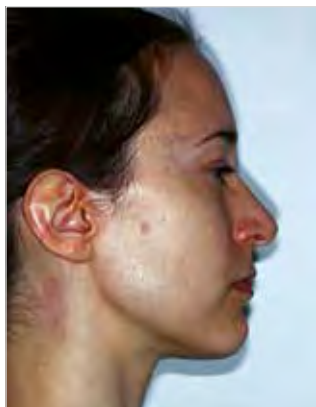Close her open bite while maintaining vertical relationship of upper anterior incisors.

Appliance Used: Insignia SL

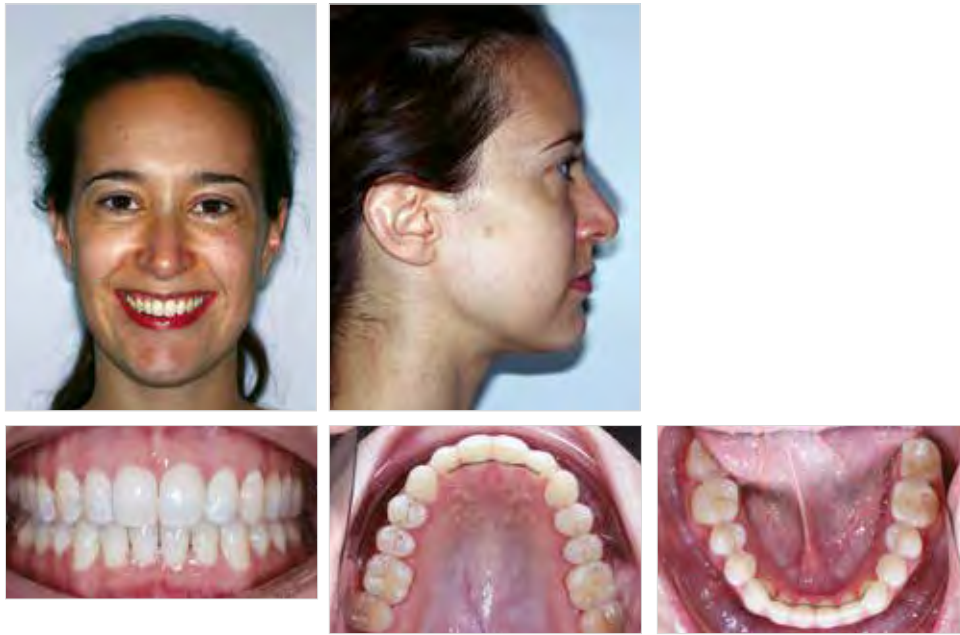Treatment plan notes submitted with this case:

- Insignia Archform
- Laterals should be shorter than centrals
- Align marginal ridges
- 3mm of overbite
- Expansion through molars and premolars
- IPR between premolars

INITIAL



FINAL



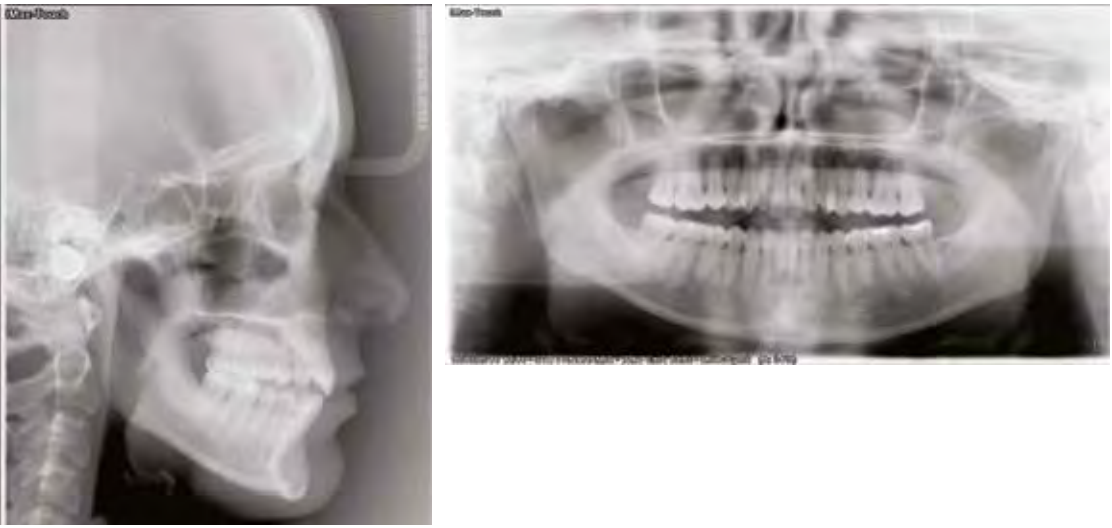
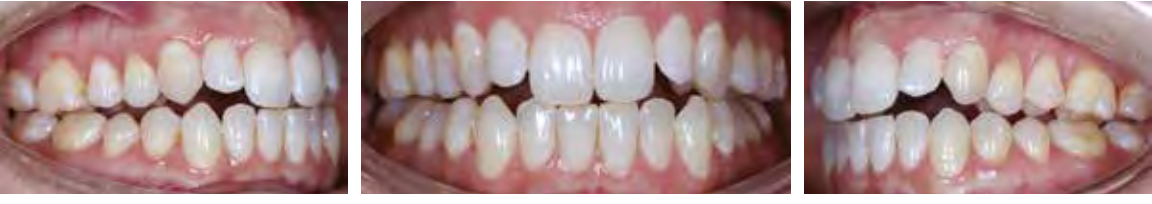TREATMENT SEQUENCE

Appointment	Archwire	Notes
1	U: .014 Damon CuNi-Ti* L: .014 Damon CuNi-Ti*	Bonding Triangle elastics
2 Week 10	U: .014 x .025 CuNi-Ti L: .014 x .025 CuNi-Ti	Triangle elastics
3 Week 22	U: .018 x .025 CuNi-Ti L: .018 x .025 CuNi-Ti	Triangle elastics
4 Week 34	U: .018 x .025 CuNi-Ti L: .018 x .025 CuNi-Ti	Triangle elastics Rebond 27
5 Week 38	U: .019 x .025 SS L: .019 x .025 SS	Anterior box elastics
6 Week 46	U: .019 x .025 SS L: .019 x .025 SS	Triangle elastics Anterior box elastics Elinks to close spaces
7 Week 57	U: .019 x .025 SS L: .019 x .025 SS	Triangle elastics Anterior box elastics IPR 2-2 Elastic chain 3-3 Occlusal adjustment
8 Week 62	U: .019 x .025 SS L: .019 x .025 SS	Debonding Fix retainer 2-2, 3-3 Occlusal splint

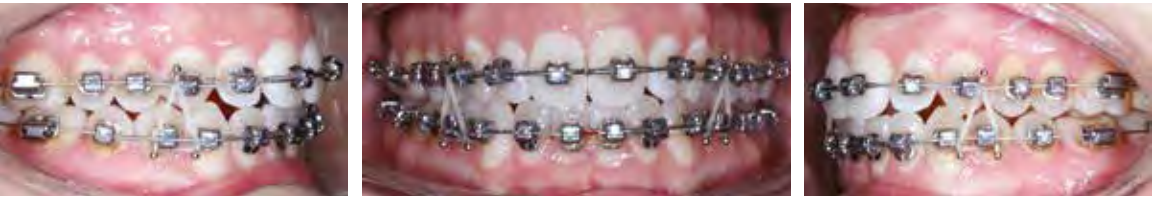*Stock round wire

Appointment photos featured in this case study

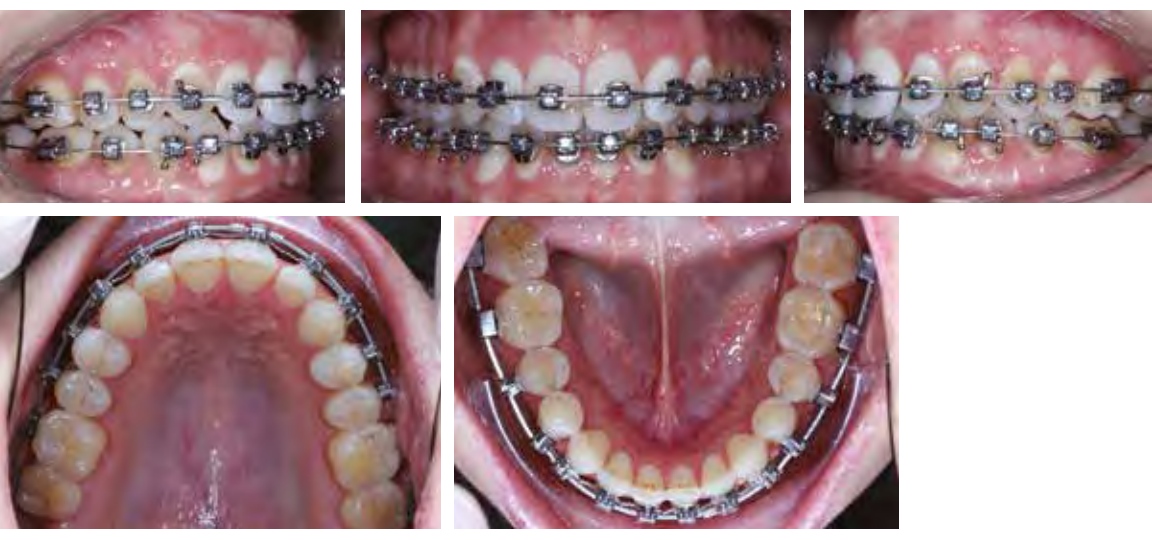INITIAL



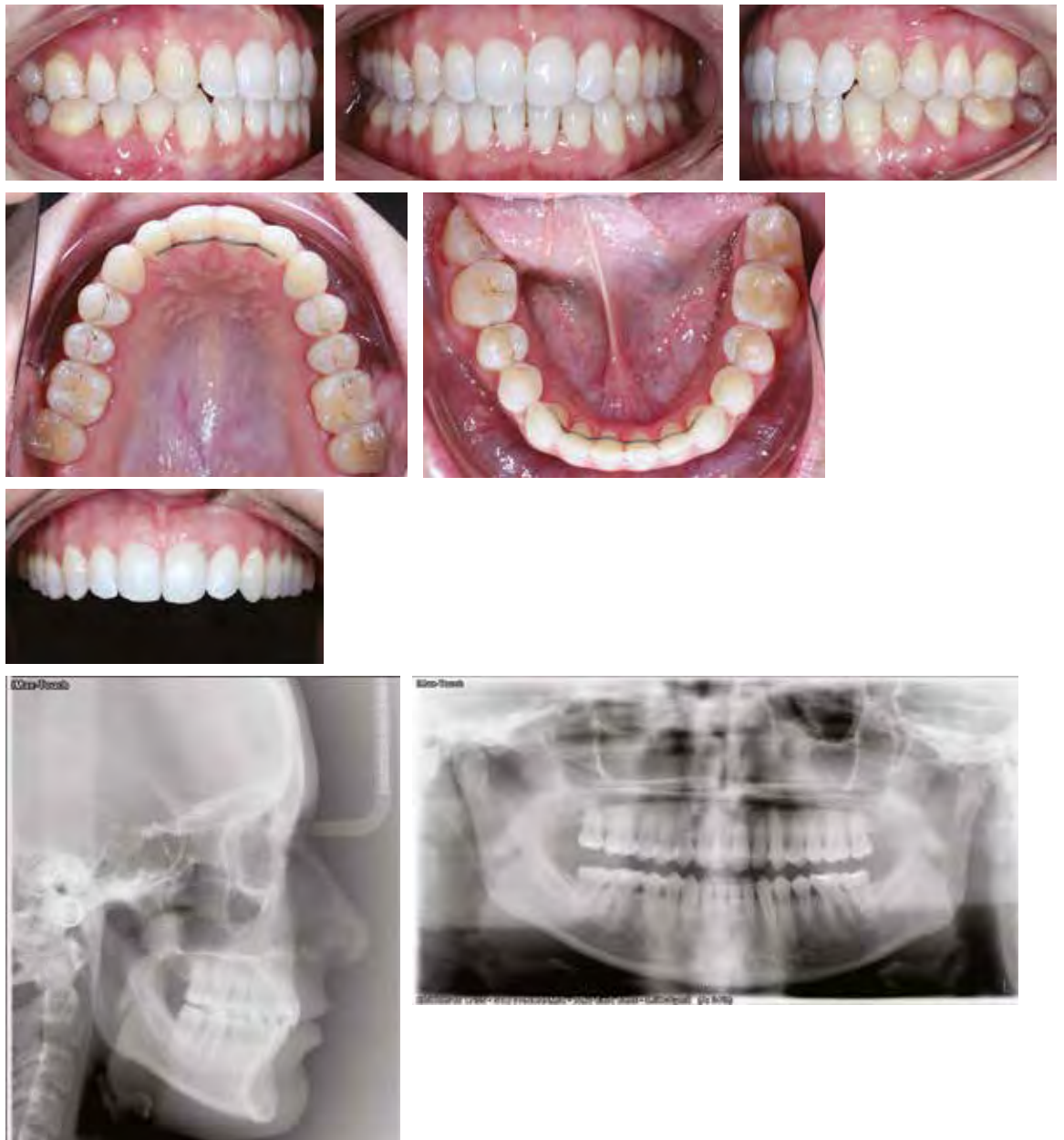
APPOINTMENT 3
2 WEEKS



APPOINTMENT 7
57 WEEKS



FINAL
62 WEEKS



Treatment Discussion

The patient had a complete open bite due to the habit of atypical swallowing.

To perform a bite closure, it is necessary to achieve perfect alignment and leveling of the teeth as well as obtaining accurate torque. Only then can we face the upper and lower occlusal planes. In addition, the two arches have been expanded at premolars and molars. The key to making a bite close quickly and easily is applying forces mesial to the arcade center of resistance, just so get a rotation of both occlusal planes.

Despite using an extrusive mechanics with previous elastics, you can see in the photo finish smile that the relationship of the upper incisors has not worsened, thanks to the relative position of the brackets at the time of cementation. The patient also followed a rehabilitation treatment neuromuscular speech pathologist, to ensure the future stability of the case.

Finishing Notes

No debonds, no wire bends. Just occlusal adjustment.

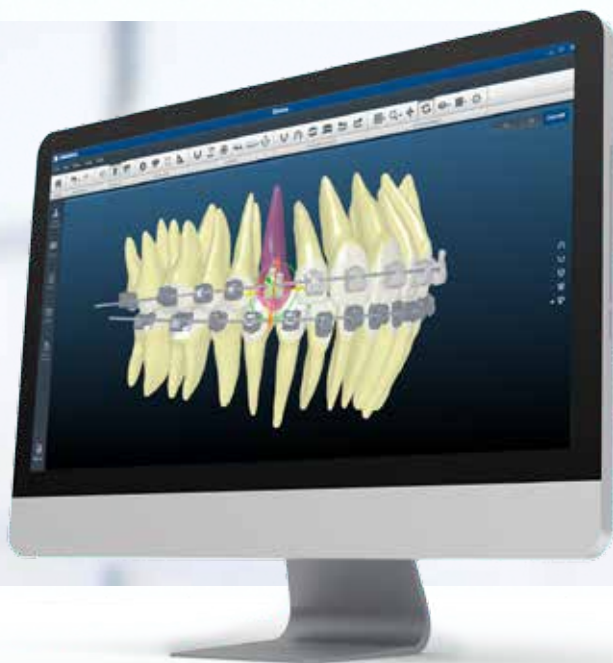

Global Users Meeting

October 19-21, 2017

New York, NY

Furthering the Discussion
on Digital Orthodontics
Today and in the Future



Dedicated to providing advanced educational content specific to leading digital orthodontists, the seventh annual Insignia Global Users Meeting will once again convene in New York City. The three-day conference will focus on the collaborative sharing of best practices, clinical insights, new tools, unrealized opportunities, and lessons learned with the leading Insignia experts and over 200 progressive orthodontists from 25+ countries. If you're an Insignia user, or are considering bringing customized orthodontics to your practice, this is the must-attend event of 2017.

Join us and discover how your peers are leveraging digital orthodontics to differentiate their practices and increase efficiency!



World-Renowned Speakers



Clinical Mentoring Sessions



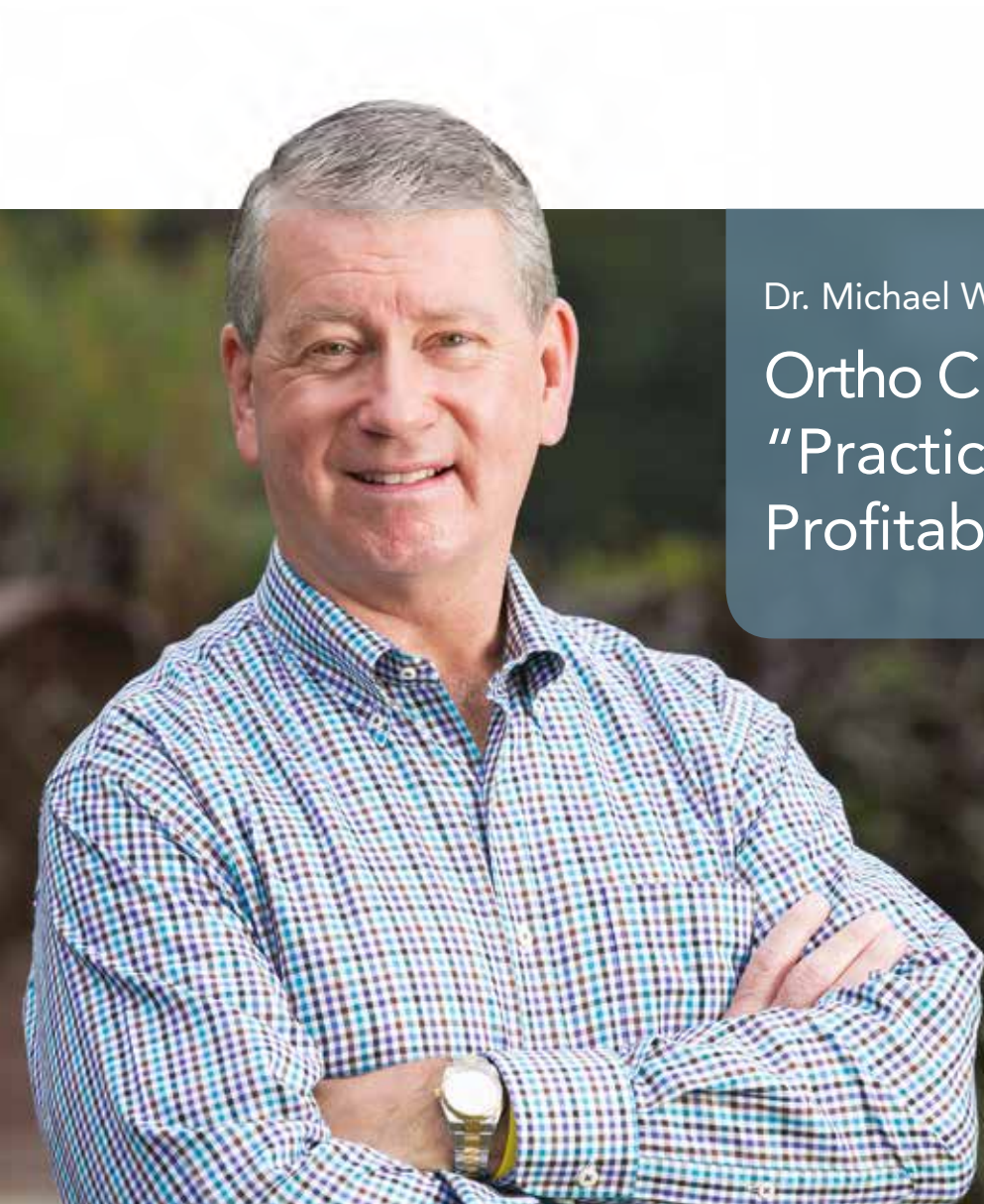One-on-One Approver Sessions



Three Impactful Days

Register Today at
ormco.com/education





Dr. Michael W. Scott

Ortho CIS™ Article Revisited: “Practice Efficiency & Profitability”

Michael W. Scott, DDS, MSD
Longview, Texas

Editor’s note: In celebration of the inaugural edition of *Clinical Impressions* 25 years ago, we thought it would be fun to take a look back into its history. This special “throwback article” is a tribute to all the doctors, writers, and industry experts who have supported *Clinical Impressions* over the years. The following excerpts are from a 1999 article that Dr. Mike Scott wrote entitled, “Practice Efficiency & Profitability: The Ortho CIS Solution” (*Clinical Impressions*, Volume 8, No 2). To commemorate this occasion, we sat down with the author to talk about his journey over the 18 years since his original article was published.

CI: As you look back on your original Ortho CIS article, what are your reactions to it today?

Dr. Scott: Well for one thing, my hair was a lot darker, but in terms of Ortho CIS, it’s interesting to note that as much as things have changed, there are so many things that have remained the same. One that pops out right away is the article’s title. When you look at buzz words in orthodontics then versus now, you still regularly find the words “efficiency and profitability” thrown around. Secondly, when I look back at my mission statement and practice goals, I’m very proud to see that I’ve stayed true to those guiding principles. Their impact on my practice has been profound. Lastly, when I look at the case I presented in that article, I am reminded of J.H. and all of the other patients whom I’ve treated with Ortho CIS over the years and realize that many of them have made as much a mark on me and my staff as we have on them.



CI: Speaking clinically, what's been the greatest constant in your practice over time?

Dr. Scott: Perhaps the greatest constant over time is the Ortho CIS bracket itself. The issues addressed in the “problems and solutions” technical report that Ortho CIS inventor Dr. Craig Andreiko published to explain the reasoning behind its design are just as applicable today as when Ortho CIS was developed. I still use the .018” slot Ortho CIS appliance and have learned that if I do what I’m supposed to do, Ortho CIS will do what it’s supposed to do.

Ortho CIS is the only preadjusted appliance ever to be based on computer-aided clinical case evaluations of actual patients and it’s a completely coordinated system of brackets and archwires, all computer-engineered. Because it was such a thoughtfully designed appliance, it hasn’t changed over the years, but advancements in supporting technologies (archwires, treatment protocols, etc.) and my own personal growth as a clinician has made Ortho CIS an even better appliance.

CI: That’s an interesting observation. How has your skill development as an orthodontist affected your treatment and mechanics?

Dr. Scott: I probably notice it most when I look back at J.H.’s treatment sequence. If J.H. were to be treated in my practice today, he’d likely see a reduction of both treatment time and number of appointments. We now routinely finish cases like his in 13 to 14 visits and 20 to 22 months. Hindsight being 20/20, I ask myself what would I do differently today. I now routinely combine treatments. Rather than using appliances in sequence, first the rapid palatal expander, then the Ortho CIS lip bumper, then braces, today I would typically bond maxillary brackets on the day of RPE insertion. In cases like this, mandibular braces would usually be added after approximately five months of lip bumper therapy. By utilizing simultaneous mechanics, we can eliminate nearly three months of extra treatment time and associated visits.

CI: You mentioned clinical growth as an orthodontist. How has this helped you over time?

Dr. Scott: I can point to four things and, again, I’ll use the J.H. case as the springboard for these lessons. First is the archwire sequence. My experience has shown that utilizing a large rectangular CuNiTi archwire at the initial appointment tends to slow down tooth movement. Whether it was the norm of the day or what, I was routinely treating cases in only two wires per arch. I think I actually did that just to be able to say I did. Back then, I also saw patients every 6 weeks. These days I appoint every 9 to 10 weeks and utilize a light .014” CuNiTi wire as my initial archwire.

Secondly, is that I’ve always been open to other ideas. One of the wonderful aspects of our profession is our willingness to learn from others. I have learned so much from the experience of other *Clinical Impressions* authors, from study club members and in academic environments. I’ve learned that while I routinely utilize expanders and sometimes lip bumpers, others may prefer IPR and other mechanics to treat similar cases. There are many ways to achieve the same treatment goals.

Thirdly, when finishing, I no longer section the maxillary archwire distal to the cuspids to enhance posterior settling. I prefer to leave the archwire intact. It’s been my experience that the work to set torques and expand arches can often be undone by running posterior elastics in the absence of a stabilizing wire in the posterior.

Lastly, as we’ve all experienced over time is the changing attitudes and motivations of our patients. While not specifically called out in the initial article, J.H. was prescribed and faithfully wore headgear. Most orthodontists would agree about its effectiveness. However, most patients today would not agree to wear headgear. Therefore today, I typically use a CI II corrector to get A/P correction.

CI: On behalf of Clinical Impressions, thank you for your contributions to the journal and to our profession. We look forward to seeing more of your work in upcoming issues.

Here are key elements of Dr. Scott's original article found in *Clinical Impressions*, Volume 8, No 2, 1999.
To download full article go to ormco.com/cisummer2017.

Practice Efficiency & Profitability

The Ortho CIS Solution

Introduction

Ortho CIS™* was introduced in 1994. The first published article about it was a 1994 *JCO* interview of Dr. Craig Andreiko by *JCO* editor Dr. Larry White. Since that time, the appliance system has enjoyed steady growth and become a worldwide leader. In this article, I'm addressing the questions that I posed to myself before becoming involved in Ortho CIS' clinical investigation: Is its clinical performance significantly superior to that of the other preadjusted appliances? Can Ortho CIS make a dramatic difference in helping me achieve my practice goals? I practiced 12 years with an excellent preadjusted appliance, one that is highly popular today, and I was not interested in changing my established technique for the sake of marginal improvements. So I can best demonstrate what Ortho CIS has added to my practice by describing its contributions to clinical performance and achievement of my practice goals.

If You Don't Know Where You're Going, How Do You Know When You're There?

As orthodontists, we are truly blessed to be in such a great profession. We are also charged with the responsibility of delivering the best smile possible to every patient. I've truly enjoyed building my practice, and I attribute the enjoyment and success that I've experienced to establishing specific priorities and goals, working to achieve them and constantly measuring my performance against them. As I share my goals with you, I imagine many of you will find them consistent with your own.

First, I have a mission statement:

1. I will deliver the best orthodontic care available in the cities that I serve.
2. That care will be provided in a manner that will be recognized by both the patient and/or parents as the best there is. The relationship of my office to each patient is vitally important to the continued growth of my practice.
3. I will provide that care to an ever-growing number of patients.
4. I will make a reasonable profit.

My practice goals are separate from my mission statement, yet totally connected:

1. Produce consistent, predictable, high-quality orthodontic results.
2. Start all the cases I care to start.
3. Make a reasonable profit.
4. Practice with great efficiency.
5. Have fun.

Note that profitability is on both lists.

* Products identified as "Ortho CIS" are distributed in Europe as "Ortho-CIS."

Ortho CIS Solutions to Commonly Encountered Orthodontic Problems

Problem: *Consistency achieving proper root alignment in lower anterior region.* If one looks at the initial panoramic radiograph of the typical orthodontic patient, significant convergence of the lower incisor and cuspid roots is readily apparent. That is, there is a significant mesial root inclination (Figure 16). Most preadjusted appliance systems have “universal” lower incisor brackets with zero degrees of distal root tip (Figure 17), making root paralleling difficult. The orthodontist is forced to overcome the limitations of the appliance by “tweaking” the brackets during bonding to try to place 2° to 4° of distal root tip into the placement of the bracket. I am 44 years old – I need glasses with extra magnification just to see the brackets! There

is no way I can see 2° to 4°. If it can be built in, that is a huge plus.

Solution: *Progressive distal root tip is built into all lower anterior brackets to achieve improved uniformity in root spacing.* Ortho CIS overcomes the problem by placing progressive distal root tip into the lower incisor and cuspid brackets (Figures 18-20). There are no universal brackets for the Ortho CIS lower anteriors, or for any other tooth for that matter. This does not pose an inventory problem since it requires no more inventory than would a universal system. If you need four lower incisor brackets, that’s all you need to have in stock. They’re just tooth specific.



Figure 16. Mesial root inclination seen in lower anteriors prior to treatment.

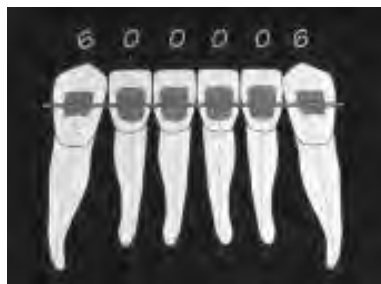

Figure 17. “Universal” lower incisor brackets with 0° distal root tip.

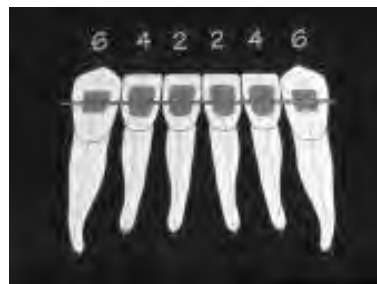

Figure 18. Tooth-specific Ortho CIS lower anterior brackets with progressive distal root tip.



Figure 19. Lower anterior root alignment problems seen on progress Panorex when using non-Ortho CIS lower anterior brackets.



Figure 20. Lower anterior root alignment commonly seen on progress Panorex when using Ortho CIS lower anterior brackets.

Problem: *Difficulty achieving coordination of upper and lower arches, especially during finishing.* This is a common problem with many preadjusted appliance systems and is due to a number of factors.

First, there are several preadjusted appliances that actually lack an associated arch form. The orthodontist has to choose which one to use. Most currently popular arch forms spring from three sources:

- Some orthodontic guru's idea of what is correct
- A catenary curve
- Shape of the end of an egg (trifocal ellipse)

Solution: *Ortho CIS arch forms and brackets are computer-derived from skeletal analysis and are integrally designed to coordinate the dental arches.* Anthropological studies of human skeletal anatomy were the source of the data from which Ortho CIS arch forms were derived. The lower arch form positions the mandibular teeth in the center of the alveolar bone of the mandible, the Mantroff. Mandibular buccal cusps are positioned to form a smooth arch that truly reflects the size and

shape of the mandible. The upper arch form then occludes the maxillary teeth to the mandibular cusp arch form (Figures 34-35). There are two upper and two lower arch forms in order to make the most precise "average arch form" somewhat patient specific, to give better coverage to the left and right of the top of the bell curve into which more dentitions fall (Figure 36).

It is this integration of computer-derived arch form and bracket design that optimizes clinical finishing. Ortho CIS is unchallenged as a finishing appliance.

It separates itself from the crowd in the final stages of treatment. Here is where all the slight to moderate differences built into Ortho CIS deliver the best clinical finishing available. It is during the final weeks of treatment, when the patient is growing weary of braces, that many appliances demand a high degree of patient cooperation in the wearing of finishing elastics. This is where the case may be finished wonderfully or just okay, and Ortho CIS significantly reduces the level of patient cooperation required by other appliances. A comment heard time and time again from long-time Ortho CIS users is "the teeth just fit together better."

Continued on page 34

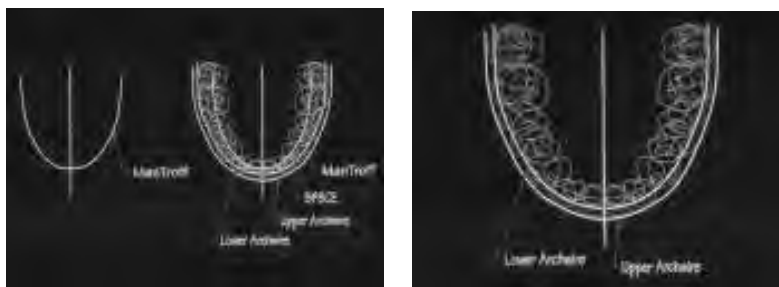


Figure 34-35. Computer-derived depictions of Mantroff, BFBCE and maxillary and mandibular arch forms.

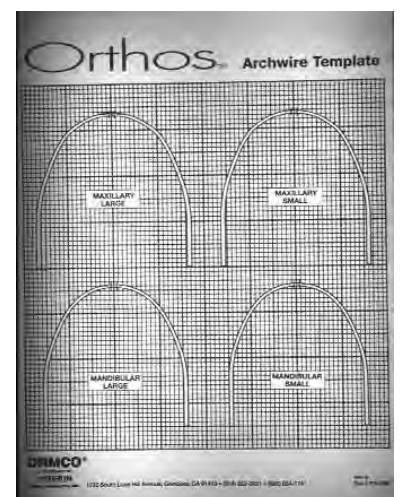


Figure 36. Ortho CIS arch form template.

AOA

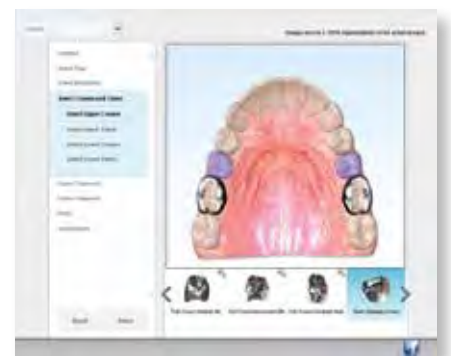

SAY GOODBYE TO
YOUR FORMER RX!

Experience A New Way of Submitting Cases with AOA Access

- Provides images or descriptions to assist in predictable appliance design selections.
- Great educational tool for offices. Helps in determining the right appliance for the patient.
- Establishes and maintains appliance presets to make individual case submission easy.

Contact your **Ormco/AOA Representative**
or visit **aoaaccess.com** to learn more.



For a demo, go to **aoaaccess.com**
and click on Site Tour.



Ortho CIS Case Presentation Patient J.H., age 13 years, 5 months

DIAGNOSIS

Skeletal

- Class II skeletal growth pattern
- Retrognathic mandible

Dental

- Moderate mandibular crowding
- Deep curve of Spee
- Vertical overbite = 6 mm
- Maxillary cuspids erupting high and labially
- Over-retained primary cuspids
- Maxillary left 2nd bicuspid rotated 90°
- Mandibular midline shifted left 3 mm

TREATMENT PLAN

- Extract maxillary primary cuspids
- Nonextraction therapy using Ortho CIS
- Rapid palatal expander
- Lip bumper
- Anticipated treatment time = 24 months

TREATMENT SUMMARY

- 16 appointments
- 24 months
- RPE alone – 12 weeks
- Lip bumper – 21 weeks
- Maxillary appliances – 97 weeks
- Mandibular appliances – 77 weeks

ARCHWIRE SEQUENCES

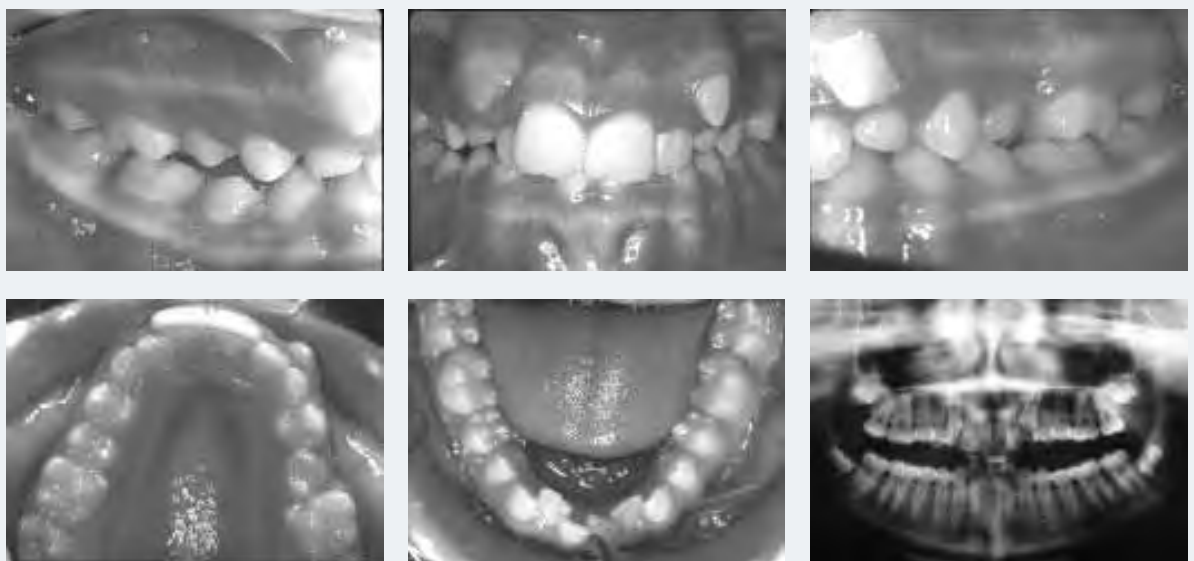
Maxillary Arch

.017 x .025 35°C Copper Ni-Ti – 10 appointments, 75 weeks
.017 x .025 S.S. – 4 appointments, 22 weeks

Mandibular Arch

.016 x .022 35°C Copper Ni-Ti – 6 appointments, 42 weeks
.017 x .025 S.S. – 5 appointments, 35 weeks

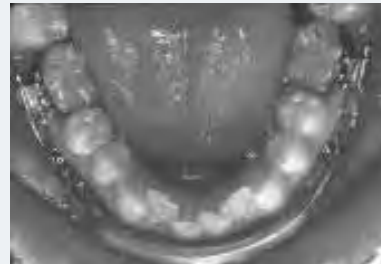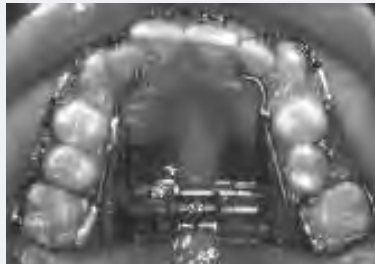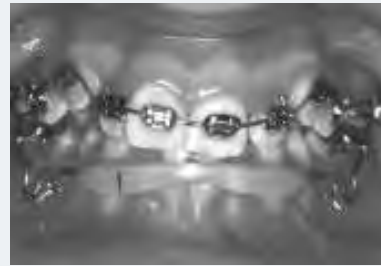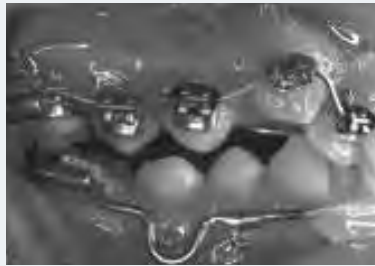
Pretreatment



Case in Progress

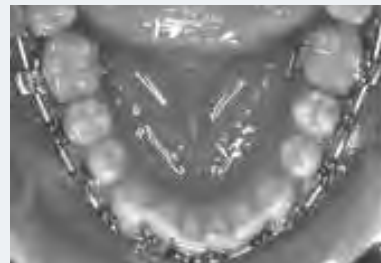
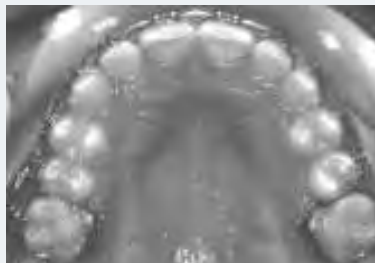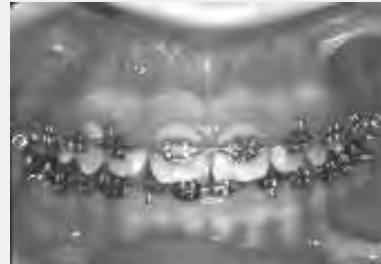Appointment #3, week 12

Bonded upper 5 to 5 with Ortho CIS brackets. Placed an .017 x .025 35°C Copper Ni-Ti upper archwire. Seated lip bumper in previously bonded lower 1st molars.



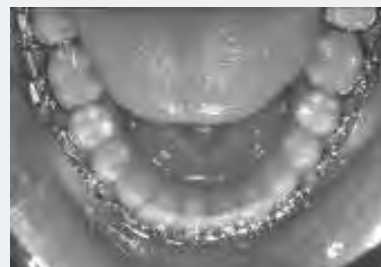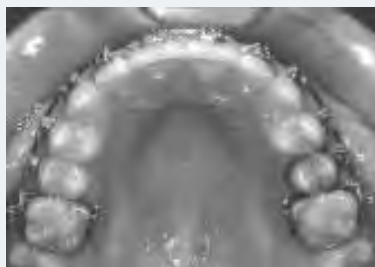
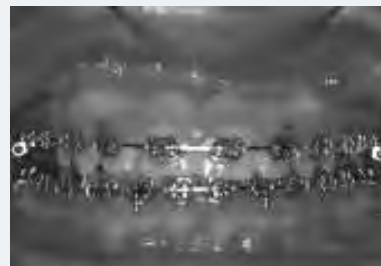Appointment #6, week 32

Removed RPE and discontinued lip bumper therapy. Bonded and banded lower arch and placed an .016 x .022 35°C Copper Ni-Ti archwire. Placed Power Chains 6 to 6 in upper arch.

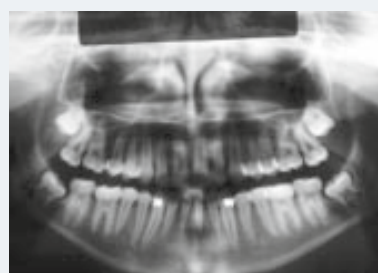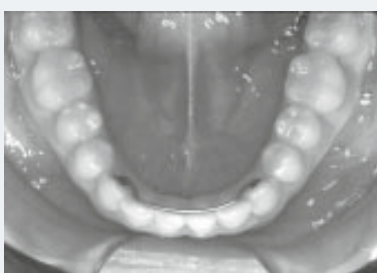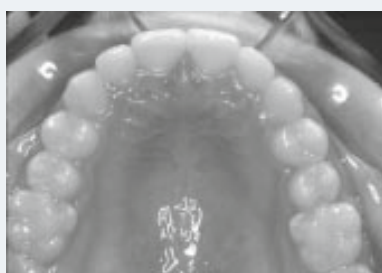


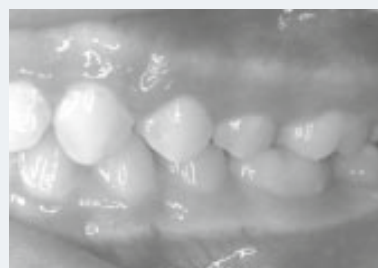
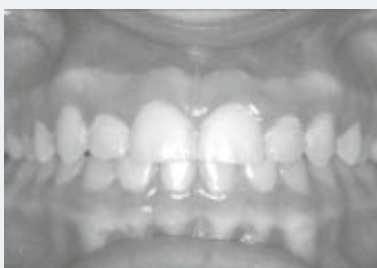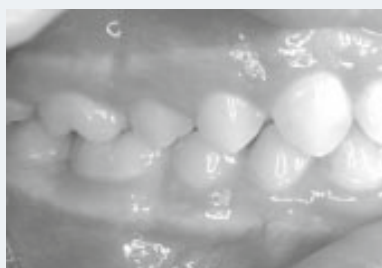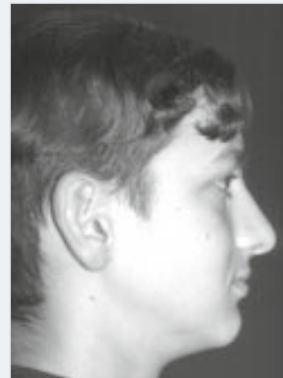Appointment #14, week 98

An .017 x .025 S.S. upper archwire had been placed at the previous appointment. Placed an .017 x .025 S.S. lower archwire.



Posttreatment
(eight weeks
after debanding)



To read the article in its entirety, go to ormco.com/cisummer2017

AOA

COMING SOON
NITI CAD/CAM
LINGUAL RETAINER

M
MEMOTAIN®

FEATURED 2017 EVENTS

JUNE

DATE	TITLE	SPEAKER(S)	LOCATION
2	How Maximum Utilization of PSL Can Make A Significant Difference in the Treatment Outcomes in Your Practice	Dr. Tom Barron	Pittsburgh, PA
9	The Marriage of Airway and PSL – Why is it a Perfect Match?	Drs. Arthur Kammerman & Mary Burns	Columbia, MD
9	The Keys for Success in Treating With Passive Self-Ligation	Dr. Frank Bogdan	New Haven, CT
9	Practice Performance – Diagnosing & Treatment Planning Your Business	Drs. Jeff Kozlowski & Jamie Reynolds	Dallas, TX
16	The Keys for Success in Treating With Passive Self-Ligation	Dr. Frank Bogdan	Little Rock, AR
23	LSU Orthodontic Alumni Meeting	Dr. Stuart Frost	New Orleans, LA
29–1	World Society of Lingual Orthodontics	Drs. Kyoto Takemoto & Giuseppe Scuzzo	Bangkok, Thailand
30–1	Insignia Users Meeting & Advanced PSL Mechanics	Drs. Stuart Frost & Sonia Palleck	Noosa, Australia

JULY

7	Australia Insignia Users Meeting	Dr. Sonia Palleck	Noosa, Australia
12–14	5th Annual Asian Damon Forum	Various Speakers	Bangkok, Thailand
20–22	Australian Begg Society of Orthodontists	Dr. Chris Chang	Hamilton Island, Australia
21	The Marriage of Airway and PSL – Why is it a Perfect Match?	Drs. Tom Barron & Mary Burns	Denver, CO

AUGUST

3–6	29th Annual Graduate Orthodontic Residents Program (GORP)		Cleveland, OH
11–12	Insignia Academy	Dr. Tim Bandeen	Newport Beach, CA
17–19	Australasian Society of Lingual Orthodontists	Dr. Giuseppe Scuzzo	Melbourne, Australia
25–26	Academy for Orthodontic Excellence (AOE) with San Diego Study Club	Dr. David Sarver	San Diego, CA

SEPTEMBER

7–9	European Damon Forum	Various Speakers	Larvotto, Monaco
8	Damon Academy	Dr. Todd Bovenizer & Mr. Alex Miroshnichenko	Salt Lake City, UT
8–9	American Lingual Orthodontic Association (ALOA) Annual Meeting		Las Vegas, NV
14–17	GLAO/MSO/SWSO Annual Session	Dr. David Sarver	New Orleans, LA
15	The Marriage of Airway and PSL – Why is it a Perfect Match?	Drs. Arthur Kammerman & Mary Burns	Buffalo, NY

Continued on next page

FEATURED 2017 EVENTS

SEPTEMBER

DATE	TITLE	SPEAKER(S)	LOCATION
15	Dental Depot Group Meeting	Dr. Scott Aaron	Oklahoma City, OK
15–16	Canadian Association of Orthodontists (CAO) 69th Annual Scientific Session		Toronto, ON, Canada
16–19	2nd Annual India Damon Symposium	Various Speakers	Bangalore, India
22–23	Insignia Academy	Dr. Tim Bandeen	Newport Beach, CA
22	Creating the Practice of Choice: From PSL Finishing for Superior Esthetics to Exceptional Patient Experiences	Drs. Todd Bovenizer & Bill Dischinger	Tysons Corner, VA
22–23	Practice Performance – Diagnosing & Treatment Planning Your Business	Dr. Jeff Kozlowski, Dr. Jamie Reynolds & Mr. Landy Chase	Chicago, IL
29	The Keys for Success in Treating With Passive Self-Ligation	Dr. Frank Bogdan	Dallas, TX

OCTOBER

5–7	Southern Association of Orthodontists (SAO) Annual Meeting		Tampa, FL
6	New England Damon Study Club	Dr. Mike Mayhew	New London, CT
11–13	Deep South Damon Study Club	Dr. Jeff Summers	Napa, CA
12–15	Pacific Coast Society of Orthodontists (PCSO) Annual Session		Reno, NV
13	Damon Academy		Newport Beach, CA
13	Practice Performance – Diagnosing & Treatment Planning Your Business	Drs. Jeff Kozlowski & Jamie Reynolds	Atlanta, GA
19–21	Insignia Global Users Meeting	Various Speakers	New York, NY
26–28	Mexico Damon Forum	Various Speakers	Mexico City, MX

NOVEMBER

3	NC/SC Damon Study Club	Dr. Jeff Summers & Ms. Debby Hartman	Raleigh, NC
9–12	Northeastern Society of Orthodontists (NESO) Annual Meeting		Boston, MA
15	Greater Philadelphia Society of Orthodontists (GPSO)	Dr. David Sarver	Philadelphia, PA
17–18	Esthetics & Finishing In-Office Course	Dr. Stuart Frost	Mesa, AZ
24–29	Greater NY Dental Meeting (GNYDM)	Dr. Jeff Kozlowski	New York, NY
1–3	Nordic Damon and Insignia Forum	Drs. Frank Bogdan & Jeff Kozlowski	Stockholm, Sweden
1–3	1st Annual Saudi Arabia Damon Symposium	Drs. Tim Bandeen & John Lin	Riyadh, Saudi Arabia

THE FORUM 2018

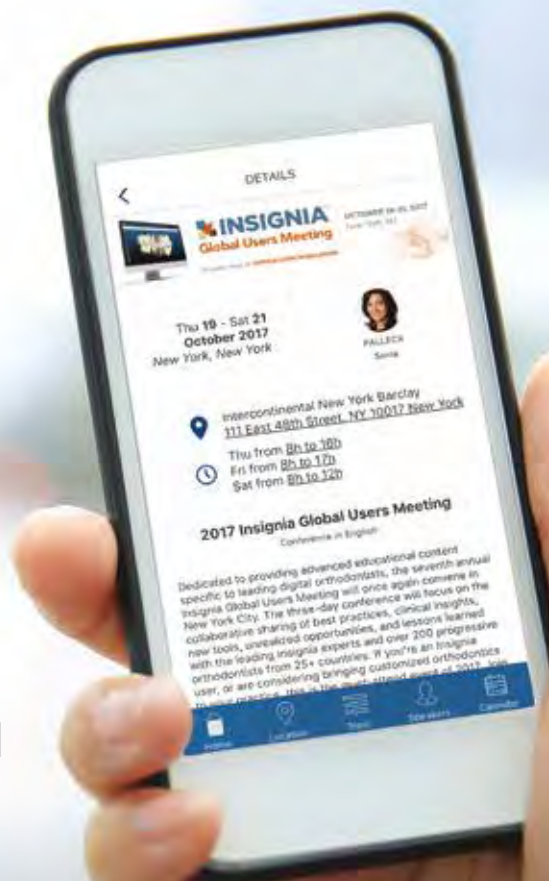FEBRUARY 14-17

PALM DESERT | CALIFORNIA

REGISTER NOW
FORUM.ORMCO.COM

Download
Ormco's
NEW Global
Education
Mobile App

Search for
ORMCO EDUCATION
in your App Store





Ormco Corporation
1717 West Collins Avenue
Orange, CA 92867

**Subscribe to
Clinical Impressions Online!**

This and future issues of *Clinical Impressions* will only be available online. To access new and archived articles, register today at ormco.com/ci.

GLOBAL SYMPOSIUMS

ORMCO
Continuing
Education

2017

THE ASIAN DAMON FORUM

Bangkok, Thailand
July 12-14

THE EUROPEAN DAMON FORUM

Monaco
September 7-9

INDIA DAMON SYMPOSIUM

Bangalore, India
September 16-19

INSIGNIA GLOBAL USERS MEETING

New York, New York
October 19-21

MEXICO DAMON FORUM

Mexico City, Mexico
October 26-28

THE NORDIC DAMON & INSIGNIA FORUM

Stockholm, Sweden
December 1-3

SAUDI ARABIA DAMON SYMPOSIUM

Riyadh, Saudi Arabia
December 1-3

2018

ORMCO FORUM

Cape Town, South Africa

February 2-4

THE FORUM 2018

Palm Desert, California

February 14-17

ORMCO FORUM RUSSIA

Saint Petersburg, Russia

June 1-3

Visit ormco.com/education
for more details.